

VASCULAR IMAGES

Endovascular treatment of thoracic aorta injury after spinal column surgery

José Miguel Martín-Pedrosa, MD, Vicente Gutiérrez, MD, José Antonio González-Fajardo, MD, and Carlos Vaquero, MD, *Valladolid, Spain*

A 61-year-old woman with a history of left dorso-lumbar scoliosis and severe dorso-lumbar kyphosis underwent surgical treatment of a spinal deformity.

Surgery was conducted on the patient by performing a dorso-lumbar spinal arthrodesis (T6-L5) by means of the insertion of two longitudinal rods and a number of pedicle-expander screws at different vertebral levels.

Following the orthopedic surgery, the patient presented paraparesis of the lower limbs and anemia that required transfusion.

In the immediate postoperative period, a noncontrast-enhanced computed tomography (CT) scan was obtained to assess the medullary canal. A deviation of the left screw placed at T6 was detected; this screw projected outward from the vertebral cortex, protruding into the descending thoracic aorta.

A contrast-enhanced CT scan showed that the screw had been malpositioned, and the image was highly suggestive of a perforation of the aortic wall, despite a lack of evidence of a peri-aortic hematoma, extravasation of contrast medium, or pleural effusion. The patient remained hemodynamically stable, and the decision was to perform an endovascular repair electively within 24 hours (A, Cover).

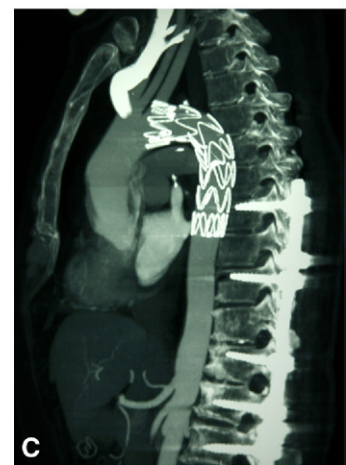
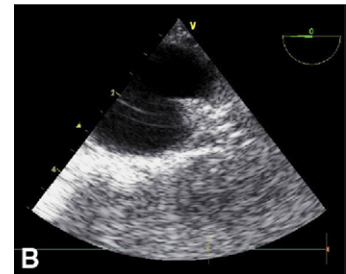
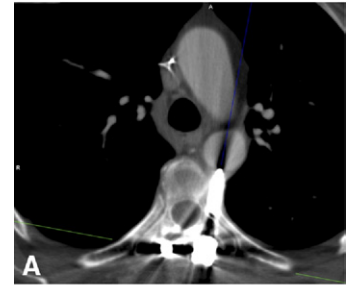
In the operating room, a transesophageal echocardiogram (TEE) showed a metal object in the uppermost portion of the descending aorta constricting the arterial wall and giving rise to a tent-shaped image. A turbulent flow beneath the arterial intima and an intramural hematoma without active bleeding were found at that level (B).

The patient was placed in a right decubitus position in the operating room to simultaneously perform the endovascular surgery of the thoracic aorta and the removal of the screw by the orthopedic surgeon.

A single 28- × 28- × 100-mm Medtronic Valiant (Medtronic, Santa Rosa, Calif) thoracic endoprosthesis was introduced through the left common femoral artery into the proximal descending thoracic aorta at the site of injury. Afterward, an orthopedic surgeon manually removed the screw placed at D6, and the endograft was then expanded with a Reliant Stent Graft Balloon Catheter (Medtronic).

There was no evidence of any leakage or signs of bleeding by TEE and intraoperative angiographic control.

During the postoperative period, the patient recovered lower limb strength and mobility, and she was discharged uneventfully within 72 hours. A follow-up contrast-enhanced CT scan that did not show signs of complications was obtained 1 month after the repair (C).



From the Department of Angiology and Vascular Surgery, University Clinic Hospital of Valladolid.

Competition of interest: none. (e-mail: martinpedrosa687@yahoo.es).

The editors and reviewers of this article have no relevant financial relationships to disclose per the JVS policy that requires reviewers to decline review of any manuscript for which they may have a competition of interest.

J Vasc Surg 2011;xx:xxx

0741-5214/\$36.00

Copyright © 2011 by the Society for Vascular Surgery.

doi:10.1016/j.jvs.2011.02.051

Iatrogenic aortic injuries after spinal column surgery are rare, but they are even less frequent after a posterior instrumentation.^{1,2}

These lesions usually are discovered in the postoperative control CT scan, although this method did not provide an accurate diagnosis. Because of this, we consider that TEE is very useful to confirm aortic wall lesions, given that it allows assessment of the aortic wall integrity. Endovascular treatment provides a less invasive and a potentially less morbid alternative to open surgery.

REFERENCES

1. Minor ME, Morrissey NJ, Peress R, Carroccio A, Ellozy S, Agarwal G, et al. Endovascular treatment of an iatrogenic thoracic aortic injury after spinal instrumentation: case report. *J Vasc Surg* 2004;39:893-6.
2. Kakkos SK, Shepard AD. Delayed presentation of aortic injury by pedicle screws: report of two cases and review of the literature. *J Vasc Surg* 2008;47:1074-82.

Submitted Dec 21, 2010; accepted Feb 19, 2011.