

## Review

## Quadrilateral plate fractures of the acetabulum: An update

Grace White<sup>a</sup>, Nikolaos K. Kanakaris<sup>a</sup>, Omar Faour<sup>b</sup>, Jose Antonio Valverde<sup>b</sup>, Miguel Angel Martin<sup>c</sup>, Peter V. Giannoudis<sup>a,\*</sup>

<sup>a</sup>Academic Department of Trauma and Orthopaedics, Clarendon Wing, Great George Street, Leeds General Infirmary, LS1 3EX, United Kingdom

<sup>b</sup>Hospital of Avila, Spain

<sup>c</sup>Clinic University Hospital of Valladolid, Spain

## ARTICLE INFO

## Article history:

Accepted 8 October 2012

## Keywords:

Quadrilateral plate

Acetabular fracture

Central hip fracture dislocation

## ABSTRACT

Acetabular fractures with quadrilateral plate involvement form a heterogeneous group of fractures, which are not specifically defined by any current classification system. Their incidence is increasing due to the rising number of elderly osteoporotic fractures. They have always been notoriously difficult fractures to treat. We present a systematic review of conservative and operative management and their respective outcomes over the last century.

© 2012 Elsevier Ltd. All rights reserved.

## Contents

Introduction .....	159
Methods .....	160
Results .....	160
Conservative treatment .....	160
Operative treatment .....	162
Pins and screws .....	162
Plates .....	163
Cerclage wiring and cables .....	163
Arthroplasty .....	163
Discussion .....	163
Conclusion .....	166
Acknowledgements .....	166
References .....	166

## Introduction

Before the mid-twentieth century, no unified classification system existed for acetabular fractures. In 1958, Knight and Smith<sup>1</sup> used the ‘clock face’ classification, followed by the ‘triradiate’, of Rowe and Lowell in 1961.<sup>2</sup> Currently the most widely and almost universally adopted system is that of Letournel and Judet, first described in 1961.<sup>3–5</sup> However, fracture type alone is not the only

determinant of outcome and other factors such as degree of comminution, displacement, and central dislocation are important with regards to management.<sup>6,7</sup>

The quadrilateral plate refers to the medial wall of the acetabulum,<sup>8</sup> and is not specifically considered as a parameter in most of the classification systems. As a bony structure it is relatively thin, with less force required to fracture it, compared to the thick superior weight bearing area.<sup>2</sup> Central fracture dislocations of the hip with medial migration of the quadrilateral plate are most frequently associated with both-column, anterior column and posterior hemitransverse, posterior column and combined transverse or T-shaped fractures.<sup>5,9–11</sup> They are reported to be more

\* Corresponding author. Tel.: +44 0113 3922750; fax: +44 0113 3923290.  
E-mail address: [pgiannoudi@aol.com](mailto:pgiannoudi@aol.com) (P.V. Giannoudis).

common in the, increasing in numbers, osteoporotic acetabular fractures.<sup>11–17</sup> These fractures of mainly the elderly population, also pose several specific treatment challenges compared to those of young high-energy trauma patients who are traditionally associated with acetabular fractures.<sup>7,12,13,18–23</sup>

Until the 1960s most acetabular fractures were treated non-operatively. Traction was first recommended by Cottloda in 1922 and represented the mainstay of management. It was the pioneering work of Judet and Letournel that resulted in operative treatment becoming the standard of care, as it is today.<sup>4,20,24</sup> The current consensus regarding the contemporary aims of acetabular fracture treatment are to relieve pain, allow early mobilisation, restore function by restoring the normal hip joint anatomy; thereby limiting the risk of early post-traumatic arthritis using the modality that offers the greatest chance of success.<sup>6,7,13,16,25,26</sup> Selection of a specific method of treatment of any acetabular fracture depends on numerous factors including age, functional status, fracture pattern, degree of displacement, associated injuries pre-existing local and general condition as well as the available surgical expertise.<sup>3,20,27</sup> Current treatment options for acetabular fractures include both conservative and operative methods. Over time, prognostic indicators of outcome have been defined and this has led to an increasing trend towards operative fixation. Techniques used include open reduction and internal fixation with pins, screws, plates and screws, percutaneous screws, cerclage wiring and cable fixation, delayed and acute total hip arthroplasty (THA).<sup>14,22</sup>

Quadrilateral plate fractures represent a heterogeneous group of acetabular fractures. Some can be reduced indirectly by reduction and stabilisation of column fractures.<sup>28</sup> However, it can be difficult to achieve a congruent reduction of the hip in those with a comminuted or free floating medial wall fracture. With regards to its anatomical reduction and stable fixation they are difficult to achieve, mainly due to its location in the true pelvis, limited bone stock, juxta-articular nature and its comminution especially in the presence of osteoporosis.<sup>4,6,10–12,28</sup> Failure to restore the buttressing function of the medial wall and reduce the central displacement results in incongruous hip and poor outcome.<sup>6,13,28,29</sup>

We present a review of the different treatment modalities and techniques used over the last century, and outcomes in these notoriously challenging central fracture dislocations with quadrilateral plate involvement.

## Methods

An internet search of MEDLINE, EMBASE and Cochrane library databases using the search terms: 'Acetabular Fracture' and 'Central Hip Dislocation', in the English language was performed on 1st August 2012. References from the literature, including all identified studies, were screened in order to retrieve other relevant publications. Two authors (GW and OF) independently performed the screening and selection of studies to be included in this review.

Exclusions included case reports, biomechanical, cadaveric studies, literature reviews, technical notes, letters to the editor, editorials and instructional course lectures. Only papers that specifically referred to acetabular fractures involving the quadrilateral plate or central dislocations were included in the study. All details regarding mechanism of injury, age, treatment, outcome, complications and duration of follow-up were recorded.

The retrieved data were grouped and are presented based on the method of management, i.e. conservative versus operative treatment. The reviewed evidence of the last group was further divided depending on the different techniques that have been described by the authors. All studies are presented in each group in a chronological order.

## Results

The literature search yielded 1573 studies out of which 16 met the inclusion criteria between the years 1956 and 2012.<sup>2,6,11,17,25,30–40</sup> They report on 353 acetabular fractures of which 213 were treated non-operatively (Table 1) and 140 treated operatively (Table 2). Various radiographic scoring techniques have been used to describe the quality of reduction<sup>18,41–45</sup> and osteoarthritic changes.<sup>18,41</sup> The most widely used functional scoring systems are the Merlé D'Aubingné – Postel and the Harris hip scores; others include the SF-12, SF-36 and the Musculoskeletal Functional Assessment.<sup>3,11,18,27,42,43,46–48</sup>

### Conservative treatment

Closed treatment of displaced central acetabular fractures has ranged from bed rest alone, manipulation and immobilisation in a spica cast, skin and skeletal traction. Both longitudinal and lateral (a Steinmann pin placed through the greater trochanter) skeletal traction have been used.<sup>31,33</sup> Retrieved data refer to 213 fractures as reported in 7 different studies<sup>2,30–34,36</sup> in between 1961 and 1976; their results are summarised in Table 1. Reported outcome of conservative treatment has been conflicting, with some authors<sup>2,31,32,36</sup> reporting satisfactory results even with failure to reduce the medial wall fragments. It was acknowledged however that satisfactory results were dependent upon the femoral head being reduced under an intact weight bearing dome.<sup>2,32</sup> In addition to these larger studies several case reports of closed treatment have cited satisfactory outcomes but often with only short term follow-up.<sup>49–55</sup> Poor results following conservative treatment, with a high incidence of pain and early osteoarthritis were reported by others.<sup>30,34,56–58</sup>

More specifically, Rowe and Lowell<sup>2</sup> in 1961 reported on twenty-nine cases of medial wall fractures. Twenty-seven patients were treated non-operatively, one underwent open reduction but the fracture was not fixed and they continued with conservative treatment and another underwent cup arthroplasty. Anatomical reduction was achieved in 82.1% and excellent or good clinical results were achieved in 89.3%. The displaced medial fragment was reduced in eight cases with manipulation but not in the remaining twenty-one cases. Results were graded as good or excellent in 18/21 cases when the medial fragment was not reduced. However when the femoral head remained centrally displaced the results were graded as fair (intermittent pain, 50% limitation of movement, modified work with radiographic evidence of mild to moderate osteoarthritis). On the basis of this, the authors felt that there was little indication for surgery in this type of fracture as long as the femoral head had been reduced and maintained under an intact acetabular dome.<sup>2</sup>

Eichenholtz and Stark<sup>31</sup> in 1964, in a review of twenty-eight central acetabular fractures treated conservatively, reported satisfactory results in 76.2% of the patients. Poor results were attributed to early weight bearing at less than one month, and the development of avascular necrosis of the femoral head. Four patients (14.3%) required salvage procedures to cup arthroplasty, hemiarthroplasty, or arthrodesis. They conceded that anatomic restoration of the inner acetabular wall is frequently impossible and that in many instances unnecessary for the achievement of satisfactory results for a prolonged period of time.<sup>31</sup>

Gothlin and Hindmarsh<sup>32</sup> in 1970 reviewed fifty-one patients with central fracture dislocations, twenty-three included only the inner wall and twenty-eight included the inner wall and superior dome. Thirty-two patients were managed with traction and nineteen with bed rest and non-weight bearing alone. Reduction was considered good if residual medial dislocation of the femoral head in relation to the superior dome was less than 1 cm, only

**Table 1**  
Summary of conservative treatment.

Study	Year	Patients	Age (years)	Follow-up (years)	Treatment	Outcome	Complications
Rowe and Lowell <sup>2</sup>	1961	28	(9–82)	6 (1–27)	27 closed reduction and conservative 1 open and conservative	<i>Clinical results</i> 25/28 good–excellent 3/29 fair <i>Anatomical results</i> 23/28 good–excellent 5/29 fair	1 thrombophlebitis 1 HO
Pearson and Hargadon <sup>30</sup>	1962	23	43.9 (15–77)	1.9 (1–5)	11 reduction and skeletal traction 12 bed rest and Russell traction	15/23 pain 20/23 reduced ROM 19/23 osteoarthritis	75% developed pin tract infection
Eichenholtz and Stark <sup>31</sup>	1964	21	(17–64)	4 (1–47)	20 skeletal traction 3 skin traction 2 manipulation 1 cast 2 bed rest	16/21 satisfactory 5/21 unsatisfactory	2 deaths
Gothlin and Hindmarsh <sup>32</sup>	1970	51	(16–76)	6 (3–12)	32 skeletal traction 19 bed rest	37/51 no or mild 10/51 moderate 4/51 severe functional limitations 25/51 no or insignificant pain 17/51 mild pain 9/51 severe pain 17/51 moderate to severe OA 34/51 no or mild OA	
Larson <sup>36</sup>	1973	30	n/a	5	30 skeletal traction × 3–8 weeks	<i>Inner wall displaced and intact dome</i> 9/9 good function <i>Inner wall and partial dome displacement</i> 12/12 head re-dislocated centrally 9/12 acceptable function 9/12 restricted ROM 5/12 secondary surgery – THA <i>Inner wall explosion types</i> 8/9 satisfactory results 9/9 restricted ROM 1/9 secondary surgery – THA	21/30 re-dislocation of the head post traction removal 0/30 avascular necrosis 0/30 nerve injury
Carnesale <sup>33</sup>	1975	45	(15–75)	8.6 (1–43)	Manipulation, traction, cast	7/45 good 18/45 satisfactory 15/45 unsatisfactory	1 peroneal nerve palsy 1 loss of reduction
Batra <sup>34</sup>	1976	15	48.7 (19–70)	5.7 (3–10)	14 skeletal traction 1 skin traction	2/15 satisfactory (DAP) 13/15 unsatisfactory (DAP)	

DAP – D'Aubingné and Postel score; HO – heterotopic ossification; OA – osteoarthritis; ROM – range of movement; THA – total hip arthroplasty.

60.7% were well reduced. They considered the prognosis to be relatively good as 72% had no or only mild functional limitation, 18% had severe pain and 33.3% had moderate to severe osteoarthritis at six year follow-up. Noting that those with higher grade dislocations and failure to reduce the superior weight bearing dome did worse, they felt that surgery may improve the outcome in this group.<sup>32</sup>

Larson<sup>36</sup> in 1973 reported the results of thirty non-operatively managed central fracture dislocations. Nine were classified as inner wall fractures with sufficient superior dome to maintain reduction of the femoral head using skeletal traction for three to six weeks. All were described as having a normal functioning painless hip at five year follow-up. Twelve patients had partial dome displacements, with insufficient coverage of the femoral head to maintain reduction. Traction was continued for six to eight weeks but it failed to reduce the acetabular fragments and in most cases the head re-dislocated medially when the traction was removed. Despite this, 75% were still described as having acceptable results at follow-up with only mild discomfort and restriction of range of movement. Nine patients were described as having explosion type fractures where the entire head and acetabulum were driven medially but with some congruity of the acetabular fragments to the femoral head. Traction did not realign the fragments but was

used to allow fracture healing and prevent further displacement. The results in this group were also described as satisfactory.

Carnesale et al.<sup>33</sup> in 1975 performed a retrospective review of central fracture dislocations treated at the Campbell clinic (including those previously reported by Knight and Smith<sup>1</sup> and Stewart and Milford<sup>59</sup>). Forty-five patients were treated non-operatively, including manipulative casting and traction; 15.6% were described as having a good result, 40% as having a satisfactory result (with minimal or no pain, 50–75% range of hip movement and moderate arthrosis), and 33.3% an unsatisfactory result (with pain and severe degenerative changes), of whom 20% required late arthrodesis or arthroplasty. They concluded that the results of closed treatment are satisfactory provided that the femoral head is reduced and maintained under the weight bearing dome and that when this cannot be achieved open reduction is justified.<sup>33</sup>

However, a number of authors have been disappointed by the relatively high proportion of poor results and the rapid progress of post-traumatic degenerative changes following conservative treatment. Stewart and Milford<sup>59</sup> in 1954 reported the results of eighteen patients treated non-operatively. 50% patients achieved good or excellent outcomes, 5.6% a fair and 44.4% a poor outcome. 16.7% developed avascular necrosis and 55.6% developed osteoarthritis.<sup>59</sup>

**Table 2**  
Summary of operative treatment.

Study	Year	Patients	Age (years)	Follow-up (years)	Treatment	Outcome	Complications
<i>Screws and pins</i> Okelberry <sup>35</sup>	1956	7	Unknown	(0.5–4)	Single screw	4 satisfactory 3 unsatisfactory	
Eichenholtz and Stark <sup>31</sup>	1964	3	(17–64)	4 (1–47)	Screws, pins, staples	3 unsatisfactory	1 loss of fixation 1 unable to secure fixation 1 femoral head damage and OA
Larson <sup>36</sup>	1973	6	Unknown	5	Pins	4 satisfactory 2 unsatisfactory	
Lind van Wijngaarden and Wittebol <sup>37</sup>	1973	4	40.3 (22–69)	(3–4)	Screws	3 satisfactory 1 unsatisfactory (AVN)	
Mouhsine et al. <sup>25</sup>	2005	18	81 (67–90)	3.5 (2–5)	Percutaneous screws	17 satisfactory (DAP) 1 unsatisfactory (DAP)	None
Ruan et al. <sup>38</sup>	2012	5	Unknown	1	Percutaneous screws	5 satisfactory	None
<i>Plates</i> Lind van Wijngaarden and Wittebol <sup>37</sup>	1973	4	43.8 (28–59)	(3–4)	Plates	2 restricted ROM 1 OA None had pain	
Batra <sup>34</sup>	1976	7	33.4 (18–48)	6.3 (3–11)	6 plates 1 screws alone	4 satisfactory (DAP) 3 unsatisfactory (DAP)	1 infection
Laflamme et al. <sup>11</sup>	2011	21	64.3 (55–82)	4.2	Plates	11 anatomic reduction (<1 mm) 92.9% satisfactory DAP 70.6% satisfactory HHS	2 loss of reduction 1 obturator nerve injury 2 mild HO
Keel et al. <sup>39</sup>	2012	20	59 (17–90)	0.75	Plates	19/20 anatomically reduced	3 neurological deficits (resolved)
<i>Cerclage wires and cables</i> Chen et al. <sup>40</sup>	2001	35	43 (19–72)	3.3 (1.5–5.8)	Cerclage wires and plates	35 anatomic reduction (<2 mm) 35 satisfactory HHS	2 haematoma 2 superficial infection 3 mild HO
Farid <sup>6</sup>	2010	5	(16–65)	3	Cerclage wire and spring plate	5 excellent reduction and stable fixation	
<i>Total hip arthroplasty</i> Eichenholtz and Stark <sup>31</sup>	1964	2	52 (46–58)	3 (1–5)	Early vitallium cup arthroplasty	2 satisfactory outcome 1 mild restriction ROM	1 mild HO
Cornell <sup>17</sup>	2005	3	83 (75–88)	2.7 (1–5)	Acute THA	3 satisfactory	

AVN – avascular necrosis; DAP – D'Aubigné and Postel score; HHS – Harris hip score; HO – heterotopic ossification; OA – osteoarthritis; ROM – range of movement; THA – total hip arthroplasty.

These results were not included in our Table 1, as the same patients were reported in the study by Carnesale in 1975.<sup>33</sup>

Pearson and Hargadon<sup>30</sup> in 1962 found a high incidence of pin tract infection with combined longitudinal and lateral skeletal traction maintained for six to twelve weeks in eleven patients with central fracture dislocations. Reduction was maintained in only one patient. In twelve patients no attempt was made to reduce the fracture, they were treated with bed rest and Russell traction. Overall, 65% (15/23 patients) had symptoms of varying severity, only 34.8% had no pain, 87% had a reduced range of movement and 82.6% developed osteoarthritis. They concluded that conservative treatment of central fractures does not lead to good results.

Batra<sup>34</sup> in 1976 reported the outcome over a follow up of 5.7 years of fifteen patients who underwent manipulative reduction and skeletal traction (one case was treated with skin traction). Using the D'Aubigné and Postel scoring system (as modified by Charnley), only two patients had a satisfactory result; both had only minimal initial displacement of the fracture. The remainder had variable amounts of pain, deformity, osteoarthritis and protrusio at follow-up. Damage to the weight bearing roof of the acetabulum in particular correlated with the worst results and

was associated with salvage procedures including arthroplasty and arthrodesis.

#### Operative treatment

Reported techniques included traditional lag screws alone, percutaneous screws, plates and screws, cerclage wires and braided cables. These refer to 140 different cases as reported in 12 studies<sup>6,11,17,25,31,34–40</sup> published between the years 1956 and 2012 (Table 2).

#### Pins and screws

Okelberry<sup>35</sup> in 1956 was one of the first to report on the use of screws alone to fix fractures of the medial wall. In seven patients he used an iliofemoral approach and fixed the fracture using a single screw, placed obliquely backward and medially a short distance above the acetabulum. He noted that in comminuted floor fragments more than one screw may be required. At 6 month to 4 year follow-up a satisfactory outcome was described in four patients, osteoarthritis had developed in three where incomplete reduction was achieved. The author made the point that the

fractures which are most likely to fail are those with extensive comminution to the floor and roof of the acetabulum.

Eichenholtz and Stark<sup>31</sup> in 1964 used screws, pins and staples in three cases of central fracture dislocation. In one case they were unable to fix the fracture due to its comminution, in the second screws were used but they were unable to maintain the reduction, both cases were reported to have a satisfactory result with traction. In the final case Knowles pins and staples were used which provided stable fixation but due to femoral head damage, early degenerative changes occurred and arthroplasty was performed at 13 months.

Larson<sup>36</sup> in 1973 noted that the success of fixation is dependent upon the ability of the fragments to retain fixation. In his six cases pins were used and only 66% of these patients were reported to have a satisfactory result at a five year follow-up.

Lind van Wijngaarden and Wittebol<sup>37</sup> at the same year reported on the use of screws alone in transverse fractures with quadrilateral plate involvement and central dislocation in four patients. One developed marked avascular necrosis and osteoarthritis requiring arthrodesis, the remaining three had a satisfactory outcome with 4 year follow-up. However traction was maintained for 12 weeks post-operatively and weight bearing allowed only after 8–12 months.

Mouhsine et al.<sup>25</sup> in 2005 achieved satisfactory radiological and clinical results with percutaneous screws in 17/18 elderly patients with transverse, T-type or both column fractures with minimal (<2 mm) initial displacement. There were no complications, all fractures healed with no secondary displacement, degenerative changes or screw failure.

Lately, Ruan et al.<sup>38</sup> reported satisfactory results in five patients with quadrilateral plate fractures using 3D fluoroscopic navigation and fixation with percutaneous screws positioned perpendicular to the fracture lines and close to the joint surface.

### Plates

In their study of 1973 Lind van Wijngaarden and Wittebol<sup>37</sup> reported also their results in four transverse fractures with quadrilateral plate involvement fixed over a posterior approach with plates. Whilst none had pain, two had a restricted range of movement and one had radiological evidence of marked osteoarthritis. Traction was maintained for 12 weeks post-operatively and full weight bearing was allowed only after 8–12 months.

Batra<sup>34</sup> in 1976 found unsatisfactory outcomes in his series of fifteen conservatively treated patients. He treated eight patients operatively, all with central fracture dislocations including anterior, posterior, both column and transverse fractures. All were severely displaced with roof injuries. They underwent open reduction by either the Smith Peterson or Kocher-Langenbeck approach. In one case an inappropriate approach was chosen which meant the procedure was aborted, this patient had a poor result. In the remainder, six fractures were fixed with Sherman plates and one case with screws alone. Average follow-up was 7.1 years (3–13 years). There were four satisfactory D'Aubigné and Postel scores and three unsatisfactory outcomes. The poor results were secondary to two failed reductions and one case of infection and osteomyelitis which resulted in removal of the metalwork. He felt that<sup>34</sup> open reduction especially in those with roof damage appeared to be a more rational approach but that not all patients requiring treatment will be fit or suitable.

In 2011 Laflamme et al.<sup>11</sup> reported on the outcome of displaced fractures of the quadrilateral plate in twenty-one patients over the age of 60 years and/or with an established diagnosis of osteoporosis. They used a modified Stoppa approach through which an infrapectineal plating technique was performed. Reduction was anatomical (<1 mm) in 52.4%, imperfect (1–3 mm) in 38.1% and poor (>3 mm) in 9.5%. The mean D'Aubigné and Postel

score was 16.8 with 92.9% achieving good to excellent results, the mean Harris hip score was 86.2 with 70.6% achieving good to excellent results. There were two cases with loss of reduction resulting in total hip replacement. At 4 years 19% had developed mild degenerative changes. They concluded that plating of osteoporotic fractures can yield good functional and radiological results even with an imperfect reduction as long as the femoral head remains concentric with the superior dome.

Keel et al.<sup>39</sup> in 2012 have recently described their results using the pararectus approach for fractures involving the anterior column and quadrilateral plate. Twenty patients were included in the study with an average age of 59 years. Reconstruction 3.5 mm plates and cortical screws were used through the fifth window of this new approach to allow bridging and buttressing of the quadrilateral plate. Anatomical reduction was achieved in 95% and all fractures healed.

### Cerclage wiring and cables

Cerclage wires and cables have been used either alone, in conjunction with plates and screws or combined with acute arthroplasty to provide stable fixation of the acetabular component.<sup>10,15,40,60,61</sup>

In 2001 Chen et al.<sup>40</sup> reported the outcomes of cerclage wiring combined with reconstruction plates and screws. In thirty-five both column fractures a triradiate approach with trochanteric osteotomy was used and the displaced quadrilateral plate was reduced and fixed with 1.6 mm cerclage wires. One or two reconstruction plates and screws were used to supplement the fixation as the wire alone was unable to stabilise comminuted fragments satisfactorily. All cases had a congruent reduction with no articular steps or gaps >2 mm. At an average 3 year follow-up all had good or excellent functional results, with no cases of symptomatic osteoarthritis or avascular necrosis.

Farid<sup>6</sup> in 2010 described a spring plate-cerclage wire construct. The plate acts to buttress the medial wall and the plate hole serves as a pulley to deviate the wire to provide a satisfactory line of pull against the quadrilateral plate. He describes excellent reduction and stable fixation through a sub-inguinal approach in five patients, aged between 16 and 65 years of age. He felt that this technique provides rigid fixation of difficult comminuted and osteoporotic medial wall fractures.

### Arthroplasty

THA may be performed either primarily in the acute setting or secondarily as a delayed procedure if post-traumatic osteoarthritis develops. There are no studies that specifically report on delayed arthroplasty for fractures involving the quadrilateral plate.

One of the earliest studies to discuss results following acute arthroplasty for central fracture dislocations was Eichenholtz and Stark in 1964,<sup>31</sup> which used vitallium cup arthroplasty in two cases. Both patients were reported to be pain free after 2–7 year follow-up.

Cornell<sup>17</sup> in 2005 reported satisfactory outcomes in three cases of acute THA performed for central fracture dislocations with quadrilateral plate involvement using an un-cemented cup in one case, augmented with plate and screw fixation of the fracture and in two cases an antiprotrusio cage. All cases required grafting using morselised graft from the autologous femoral head.

### Discussion

Over the last 50 years, following the generalised adoption of principles defined by the founders of modern pelvic and acetabular reconstruction surgery, a significant evolution in the contemporary management of acetabular fractures has occurred.<sup>3–5</sup> Specialists all over the world have followed their paradigm introducing modifications of the original surgical approaches, new reduction and fixation

techniques or alternative strategies.<sup>14,62–69</sup> The recorded outcome of these difficult fractures has significantly improved reflecting the increasing expertise and the advances of rehabilitation.<sup>12,18–20,27,43,46,70,71</sup> Acetabular fractures with elements of displacement and/or comminution of the quadrilateral plate or medial wall remain challenging especially in the presence of osteoporosis. For that reason we performed the present comprehensive review to define the course of management of this element of an acetabular fracture.

Direct comparison between studies is hampered by the definition of a satisfactory outcome, which has undoubtedly become more stringent over the years. A great variance was identified on the way fractures of the quadrilateral plate have been described, as well as on the reports of both radiological and functional outcomes. Also, the fact that the specific anatomical structure of the medial wall/quadrilateral plate is not considered separately in the gold standard classification scheme of Letournel,<sup>4</sup> does not allow summation of the reported results inbetween the different case series and a safe correlation of outcome to its different methods management. Moreover, no comparative analysis inbetween the different reduction and fixation techniques exists which would allow this review to propose an evidence based algorithm.

Only an indirect comparison of the outcomes of conservative treatment of central acetabular fracture dislocations to those of operative management can be made, as the first mostly predate the 1980s. Judet and Letournel attributed the unsatisfactory results of non-operative treatment not to the failure to reduce the dislocation but the inability to reduce and hold the acetabular fracture.<sup>4,5</sup> Traction acts by ligamentotaxis of the capsular attachments of the femoral head to the acetabulum and is often not effective in reducing the medial wall fragments.<sup>15,34</sup> Most acetabular fractures have besides elements of translation also degrees of rotation,<sup>15,17</sup> which is extremely difficult to correct. This results in malunion of the medial wall in a displaced position, loss of reduction and late displacement when traction is removed even after several months.<sup>17,72</sup>

Closed treatment of acetabular fractures remains applicable in some situations. Including certain fracture types, medical comorbidities which preclude surgical treatment<sup>22</sup> and is still used in many developing countries.<sup>73</sup> Until recently elderly patients were frequently included in the list of contra-indications to surgery and managed in traction.<sup>13,15,72</sup> This is due to the difficulties associated with fixation in osteoporotic bone and risks of surgery.<sup>15</sup> Satisfactory results can be expected with minimally displaced (<2 mm) fractures,<sup>2,13,17,21,22</sup> those with apparent congruence of the hip with a both column fracture, an acetabulum which is intact superiorly as documented by roof arc measurements and congruence of the femoral head with the roof on the three standard radiographs (AP pelvis and obturator and iliac oblique Judet views) out of traction.<sup>8,13,18,41</sup> However, a high proportion of unacceptable results have been found with non-operative treatment of elderly fractures.<sup>13,17,23</sup> Traction commits the patient to six to eight weeks of bed rest and non-weight bearing and in the elderly can be fraught with medical complications.<sup>13,15,17,25</sup> The well documented disadvantages of prolonged immobilisation in cases with neck of femur fractures exist in the elderly population with an acetabular fracture.<sup>23</sup>

Open reduction and internal fixation is considered the standard of care for most displaced acetabular fractures. The aim is to anatomically restore the joint surface as it has been clearly shown as a key factor for its future prognosis.<sup>7,18,20–22,43,46,72,74–76</sup> Several other factors have also been correlated with outcome. They include fracture type, with the worst outcomes associated with complex fractures, especially those with marked displacement and comminution; chondral and osseous lesions of the femoral head and ipsilateral femoral neck fractures.<sup>3,18,20,22,29,46</sup> Outcomes following

surgery have been found to deteriorate with delayed surgery,<sup>18,22,77</sup> morbid obesity, presence of comorbidities as well after the age of forty.<sup>18,20,22,29,46</sup> This relates to several factors including the increased incidence of medial wall fractures, comminution, associated intra-articular chondral and osseous injuries, pre-existing osteoarthritis and gaining secure fixation in osteoporotic bone.<sup>11,17,19,22</sup> Other factors related to an unfavourable outcome include delay to surgery,<sup>18,22,68</sup> morbid obesity and medical co-morbidities.<sup>22</sup>

The surgical approach to quadrilateral plate fractures is dependent on the fracture pattern, whether the quadrilateral plate remains attached to one of the columns or is a separate displaced or comminuted fragment, the column or wall which appears mostly displaced, the planned method of fixation, as well as the surgical expertise and preference.<sup>10,47</sup> A full discussion of operative approaches is beyond the scope of this review. Some early attempts at fixation of quadrilateral plate fractures attributed their failure to an incorrect approach being chosen,<sup>34</sup> which highlights the importance of careful preoperative planning. Judet and Letournel, provided a detailed guide to operative approaches based upon fracture type, which is still widely adhered to.<sup>3,4</sup> There has been a move away from extensile approaches such as the extended iliofemoral, triradiate and dual approaches due to an increased rate of complications especially in the elderly.<sup>3,4,18,21,29,42,47,78,79</sup> The ilioinguinal approach, first described by Letournel, has been the most widely used intrapelvic approach to access fractures of the quadrilateral plate. It has a relatively low complication rate but it can be associated with injury to the iliac vessels and lymphatics, lateral femoral cutaneous nerve and disruption of the inguinal ligament resulting in post-operative hernia.<sup>3,29,42,47</sup> More recently alternative approaches, advantageous to the reduction and fixation of the quadrilateral plate have been described, including the Stoppa approach.<sup>3,29,42,45,47</sup> Keel et al.<sup>39</sup> have recently described the pararectus surgical approach. Five windows are utilised, via the extraperitoneal space along the lateral border of rectus abdominis. The fifth window contains the quadrilateral plate up to the ischial spine and allows access to the plate from a medial its advantages include lack of dissection of the inguinal canal and the risk of inguinal hernia.

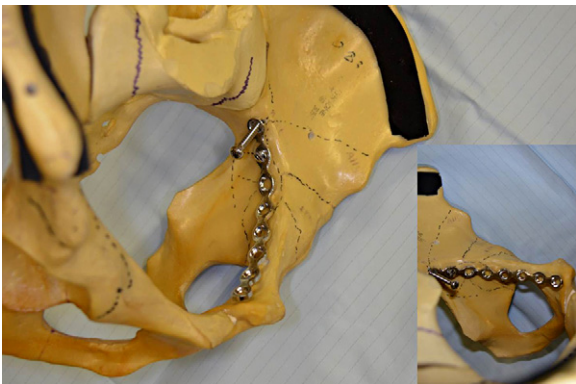Overall in those acetabular fractures where surgery is performed, development of local complications affects the outcome.<sup>20,46</sup> Infection rates are reported in around 5% of cases.<sup>3,18,20,22,79</sup> Iatrogenic nerve injury occurs in up to 10% of cases, of which the most common is the sciatic nerve.<sup>3,20,22</sup> Rates of heterotopic ossification range from 3% to 59%.<sup>3,18–22,29,79,80</sup> Risk factors include the extensile approaches, high Injury Severity Score, delay in fixation and associated head injury.<sup>20</sup> In a meta-analysis of 3639 patients treated with ORIF 26.5% went on to develop osteoarthritis and 5.6% went on to develop avascular necrosis of the femoral head.<sup>20</sup>

More specifically, regarding the fixation options of the medial wall, failure to maintain fixation using pelvic brim screws, placed parallel to the quadrilateral plate into the posterior column, has limited their role only in simple fractures with a large fragment of dense bone, in the absence of significant comminution of the medial wall or osteoporosis.<sup>18,22</sup> They can be technically difficult with risks of intra-articular penetration or/and early loss of reduction and implant failure.<sup>6</sup>

Inbetween the different techniques of plating of quadrilateral plate fractures, the use of pelvic brim plates with screws placed parallel to the quadrilateral plate has been introduced by Judet and Letournel.<sup>4</sup> A biomechanical study of the use of a conventional reconstruction plate with periarticular long screws through the quadrilateral plate, placed close to the fracture was found to be the most superior construct for preventing displacement of the medial wall and protrusion of the femoral head.<sup>64</sup> A variable angle locking



**Fig. 1.** Image of applied spring plate (3.5 mm 8 hole reconstruction plate) contoured over the pelvic brim buttressing the medial wall on a saw bone. Anchorage is provided to the iliac fossa with cortical screws.



**Fig. 2.** Infrapectineal plating (3.5 mm 8 hole) contoured below the pelvic brim, through the modified Stoppa approach for fractures involving the quadrilateral plate. Anchorage of the plate is provided with cortical screws above to the sciatic notch.

titanium pelvic brim plate was also successful in preventing medial displacement whereas fixed angle locking plates were found to be unsatisfactory, as the fixed screw trajectory made it almost impossible to place screws periarticularly.<sup>64</sup>

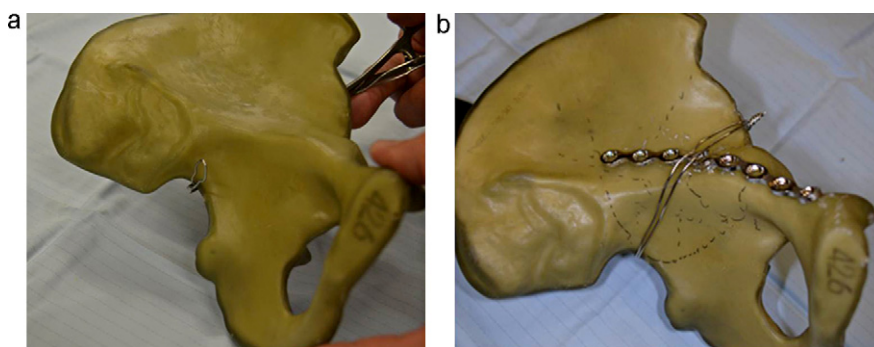
Spring plates contoured over the pelvic brim can be used to buttress the medial wall (Fig. 1). T-shaped, H-shaped, one third tubular and reconstruction plates can be all used in this manner.<sup>6,10,28,64</sup> However, these plates can be difficult to accurately contour to provide adequate medial buttress to all individuals. Failure is not uncommon, resulting in non-union and the need for secondary arthroplasty. When tested biomechanically, use of a combined pelvic brim plate with periarticular screws and an H-shape spring plate offered no advantages over use of the pelvic brim plate alone.<sup>64</sup>

Infrapectineal plating (Fig. 2) through the modified Stoppa approach for fractures involving the quadrilateral plate with medial displacement of the femoral head was a later proposition.<sup>10,11,47</sup> The plate is attached securely posteriorly using screws placed superior to the sciatic notch and anteriorly to the superior pubic ramus along the infrapectineal line. This buttresses the quadrilateral plate in the same plane as the displacement rather than perpendicular to it, helping to prevent protrusion.<sup>6,10,11,47</sup>

The use of cerclage wiring using standard stainless steel wires (Fig. 3) or cables is another alternative, reported to offer excellent reduction of the quadrilateral plate.<sup>6,40</sup> This is a less invasive technique that offers controlled indirect reduction whilst tightening the wire, extra osseous fixation eliminating the risk of joint penetration, avoiding the risk of screw cut out in osteoporotic bone and the offering the ability to address comminution.<sup>6,15,60</sup> Additional plates and screws are often required to provide stable fixation in cases of extensive comminution.<sup>6,40,60</sup>

Certain radiological features are predictive of a poor outcome following fixation, including osteoporosis and the 'Gull sign' indicating a superomedial dome impaction. Together with parameters as clear evidence of pre-existing osteoarthritis, associated femoral head and neck fracture, intra-articular comminution, full thickness abrasive loss of the articular cartilage, more than 40% impaction of the femoral head and acetabulum, extensive osteoporosis and advanced age may be relative indications for acute THA.<sup>14,15,81,82</sup>

Lately, there is growing interest in performing an initial limited ORIF and simultaneous acute THA.<sup>14,15,17</sup> The excellent radiological and functional results that have been reported were associated with low rates of aseptic loosening.<sup>16,81–83</sup> Column stability is required for secure acetabular component placement. However, absolute anatomic restoration is not required as bone grafts can be used to fill any defects, negating the need for extensile approaches.<sup>14,16,17</sup> This can be achieved using direct and indirect reduction techniques and fixation with conventional plates and screws, percutaneous screws or cerclage wires and cables.<sup>13,14,17,83,84</sup> Acetabular uncemented cups have been used as 'hemispherical plates' with screws directed in multiple planes.<sup>14,17,81,83</sup> With large bony defects and significant osteoporosis antiprotrusion cages may be required.<sup>14,82</sup>



**Fig. 3.** (a) Cerclage wire inserted using a standard anterior – ilioinguinal approach, large curved clip delivers double loop of stainless steel wire via the lateral iliac wall through the greater sciatic to the pelvis and then is caught via the 1st window of the ilioinguinal and tightened over or below the anterior inferior iliac spine. (b) It can be anchored if needed to the buttress plate of the anterior column, or according to the technique of Farid<sup>6</sup> to the last hole of a spring plate (see Fig. 1).

Studies that have combined the use of cerclage cabling have reported early cup migration of 2–3 mm but this does not seem to have affected long term results.<sup>61,83,84</sup>

Delayed hip arthroplasty following acetabular fractures with central dislocation may follow either conservative,<sup>56,85</sup> or operative fracture treatment.<sup>13,63,86–88</sup> Several authors have suggested that open reduction and internal fixation of fractures may preserve bone stock and allow easier THA if required at a later date,<sup>13,63,86–88</sup> whereas others feel that it is not necessary and complicates later arthroplasty due to dense scar tissue, heterotopic ossification, the need for hardware removal in many instances, increased operative time, blood loss, transfusion requirements and potential occult infection.<sup>15,16,63,81,84,87–90</sup> The results of THA for all types of acetabular fractures have been historically inferior to those performed for primary osteoarthritis due to higher rates of aseptic loosening.<sup>14,86,87,90,91</sup> This has been attributed to residual acetabular deformity and bony deficiency, which often require bone grafting and can make anatomic restoration of the hip centre difficult; younger age and weight over 80 kg.<sup>63,86–92</sup> Using cemented acetabular cups Romness and Lewallen<sup>86</sup> reported radiographic loosening in 52.9%, which was symptomatic in 27.5% and progressed to revision in 13.7% at 7.5 years. Use of uncemented acetabular components has provided improved results with lower rates of loosening and satisfactory outcomes with midterm survival rates of 97%.<sup>91–93</sup>

## Conclusion

What is apparent is the changing management of these fractures over the past century. Early studies used predominantly conservative methods, which yielded a considerable number of poor results for displaced fractures of the quadrilateral plate. Initial operative techniques, particularly with screws and pins also failed to achieve a high percentage of satisfactory results due to failure to achieve adequate fixation. There has been renewed interest in the minimally invasive technique of percutaneous screw fixation, either alone or to provide column stabilisation for acute THA. Plating is currently the most frequently employed method, with various operative techniques, implants and approaches now described in an attempt to improve visualisation, reduction and fixation of these challenging fractures. Whilst alternatives such as cerclage wire and cable techniques have been used, they often require supplemental fixation and acetabular component migration has been frequently noted when they have been used in conjunction with acute THA. Improved results with both early and late THA have been reported with use of uncemented acetabular components. With experience and clearly defined indications both conservative and various operative techniques have a role in the management of quadrilateral plate fractures, although there is an increasing trend towards operative management with non-extensile approaches. With the number of these fractures expected to increase there is a clear need for prospective studies with accepted outcome measures and long term follow-up to be performed.

## Conflict of interest

None to declare.

## Acknowledgements

The authors would like to acknowledge the support of Dr E. Frangakis and Dr S. Gudipati for the preparation of the images.

## References

1. Knight RA, Smith H. Central fractures of the acetabulum. *The Journal of Bone and Joint Surgery American Volume* 1958;**40-A**: 1–16 passim.
2. Rowe CR, Lowell JD. Prognosis of fractures of the acetabulum. *The Journal of Bone and Joint Surgery American Volume* 1961;**43**:30–59.
3. Letournel E, Judet R. *Fractures of the acetabulum*. 2nd ed. New York: Springer-Verlag; 1993.
4. Letournel E. Acetabulum fractures: classification and management. *Clinical Orthopaedics and Related Research* 1980;**151**:81–106.
5. Judet R, Judet J, Letournel E. Fractures of the acetabulum: classification and surgical approaches for open reduction. Preliminary report. *The Journal of Bone and Joint Surgery American Volume* 1964;**46**:1615–46.
6. Farid YR. Cerclage wire-plate composite for fixation of quadrilateral plate fractures of the acetabulum: a checkrein and pulley technique. *Journal of Orthopaedic Trauma* 2010;**24**:323–8.
7. Pennal GF, Davidson J, Garside H, Plewes J. Results of treatment of acetabular fractures. *Clinical Orthopaedics and Related Research* 1980;**151**:115–23.
8. Laflamme GY, Delisle J, Leduc S, Uzel PA. Isolated quadrilateral plate fracture: an unusual acetabular fracture. *Canadian Journal of Surgery Journal Canadien de Chirurgie* 2009;**52**:E217–9.
9. Barnes SN, Stewart MJ. Central fractures of the acetabulum: a critical analysis and review of literature. *Clinical Orthopaedics and Related Research* 1976;**114**:276–81.
10. Qureshi AA, Archdeacon MT, Jenkins MA, Infante A, DiPasquale T, Bolhofner BR. Intrapectineal plating for acetabular fractures: a technical adjunct to internal fixation. *Journal of Orthopaedic Trauma* 2004;**18**:175–8.
11. Laflamme GY, Hebert-Davies J, Rouleau D, Benoit B, Leduc S. Internal fixation of osteopenic acetabular fractures involving the quadrilateral plate. *Injury* 2011;**42**:1130–4.
12. Ferguson TA, Patel R, Bhandari M, Matta JM. Fractures of the acetabulum in patients aged 60 years and older: an epidemiological and radiological study. *The Journal of Bone and Joint Surgery British Volume* 2010;**92**:250–7.
13. Toro JB, Hierholzer C, Helfet DL. Acetabular fractures in the elderly. *Bulletin* 2004;**62**:53–7.
14. Ward AJ, Chesser TJ. The role of acute total hip arthroplasty in the treatment of acetabular fractures. *Injury* 2010;**41**:777–9.
15. Vanderschot P. Treatment options of pelvic and acetabular fractures in patients with osteoporotic bone. *Injury* 2007;**38**:497–508.
16. Strauss E. Management of acetabular fractures in the elderly. *Bulletin* 2004;**62**:47–52.
17. Cornell CN. Management of acetabular fractures in the elderly patient. *HSS Journal The Musculoskeletal Journal of Hospital for Special Surgery* 2005;**1**:25–30.
18. Matta JM. Fractures of the acetabulum: accuracy of reduction and clinical results in patients managed operatively within three weeks after the injury. *The Journal of Bone and Joint Surgery American Volume* 1996;**78**:1632–45.
19. Madhu R, Kotnis R, Al-Mousawi A, Barlow N, Deo S, Worlock P, et al. Outcome of surgery for reconstruction of fractures of the acetabulum. The time dependent effect of delay. *The Journal of Bone and Joint Surgery British Volume* 2006;**88**:1197–203.
20. Giannoudis PV, Grotz MR, Papakostidis C, Dinopoulos H. Operative treatment of displaced fractures of the acetabulum. A meta-analysis. *The Journal of Bone and Joint Surgery British Volume* 2005;**87**:2–9.
21. Helfet DL, Schmeling GJ. Management of complex acetabular fractures through single nonextensile exposures. *Clinical Orthopaedics and Related Research* 1994;**305**:58–68.
22. Mears DC, Velyvis JH, Chang CP. Displaced acetabular fractures managed operatively: indicators of outcome. *Clinical Orthopaedics and Related Research* 2003;**407**:173–86.
23. Spencer RF. Acetabular fractures in older patients. *The Journal of Bone and Joint Surgery British Volume* 1989;**71**:774–6.
24. Letournel E. Fractures of the acetabulum. A study of a series of 75 cases. 1961. *Clinical Orthopaedics and Related Research* 1994;**305**:5–9.
25. Mouhsine E, Garofalo R, Borens O, Wettstein M, Blanc CH, Fischer JF, et al. Percutaneous retrograde screwing for stabilisation of acetabular fractures. *Injury* 2005;**36**:1330–6.
26. Kumar A, Clayson AD. Irreducible central fracture dislocation of the hip: using an anterior column osteotomy for operative reduction. *Injury Extra* 2005;**36**:199–202.
27. Moed BR, Yu PH, Gruson KI. Functional outcomes of acetabular fractures. *The Journal of Bone and Joint Surgery American Volume* 2003;**85-A**:1879–83.
28. Tile M, Helfet D, Kellam J. *Fractures of the pelvis and acetabulum*. Baltimore: Lippincott Williams & Wilkins; 2003.
29. Kumar A, Shah NA, Kershaw SA, Clayson AD. Operative management of acetabular fractures. A review of 73 fractures. *Injury* 2005;**36**:605–12.
30. Pearson JR, Hargadon EJ. Fractures of the pelvis involving the floor of the acetabulum. *The Journal of Bone and Joint Surgery British Volume* 1962;**44-B**:550–61.
31. Eichenholtz SN, Stark RM. Central acetabular fractures; a review of thirty-five cases. *The Journal of Bone and Joint Surgery American Volume* 1964;**46**:695–714.
32. Gothlin G, Hindmarsh J. Central dislocation of the hip. The prognosis with conservative management. *Acta Orthopaedica Scandinavica* 1970;**41**:476–87.
33. Carnesale PG, Stewart MJ, Barnes SN. Acetabular disruption and central fracture-dislocation of the hip. A long-term study. *The Journal of Bone and Joint Surgery American Volume* 1975;**57**:1054–9.
34. Batra HC. Central fractures of the acetabulum. *Injury* 1976;**7**:171–80.



35. Okelberry AM. Fractures of the floor of the acetabulum. *The Journal of Bone and Joint Surgery American Volume* 1956;**38**:441.
36. Larson CB. Fracture dislocations of the hip. *Clinical Orthopaedics and Related Research* 1973;**92**:147–54.
37. Lind van Wijngaarden FO, Wittebol P. Operative treatment of central dislocation of the hip. *Injury* 1973;**5**:109–20.
38. Ruan Z, Luo CF, Zeng BF, Zhang CQ. Percutaneous screw fixation for the acetabular fracture with quadrilateral plate involved by three-dimensional fluoroscopy navigation: surgical technique. *Injury* 2012;**43**:517–21.
39. Keel MJ, Ecker TM, Cullmann JL, Bergmann M, Bonel HM, Buchler L, et al. The Pararectus approach for anterior intrapelvic management of acetabular fractures: an anatomical study and clinical evaluation. *The Journal of Bone and Joint Surgery British Volume* 2012;**94**:405–11.
40. Chen CM, Chiu FY, Lo WH, Chung TY. Cerclage wiring in displaced both-column fractures of the acetabulum. *Injury* 2001;**32**:391–4.
41. Matta JM, Mehne DK, Roffi R. Fractures of the acetabulum. Early results of a prospective study. *Clinical Orthopaedics and Related Research* 1986;**205**:241–50.
42. Matta JM. Operative treatment of acetabular fractures through the ilioinguinal approach. A 10-year perspective. *Clinical Orthopaedics and Related Research* 1994;**395**:10–9.
43. Mayo KA. Open reduction and internal fixation of fractures of the acetabulum. Results in 163 fractures. *Clinical Orthopaedics and Related Research* 1994;**305**:31–7.
44. Mayo KA, Letournel E, Matta JM, Mast JW, Johnson EE, Martimbeau CL. Surgical revision of malreduced acetabular fractures. *Clinical Orthopaedics and Related Research* 1994;**305**:47–52.
45. Hirvensalo E, Lindahl J, Kiljunen V. Modified and new approaches for pelvic and acetabular surgery. *Injury* 2007;**38**:431–41.
46. Liebergall M, Mosheiff R, Low J, Goldvirt M, Matan Y, Segal D. Acetabular fractures. Clinical outcome of surgical treatment. *Clinical Orthopaedics and Related Research* 1999;**366**:205–16.
47. Cole JD, Bolhofner BR. Acetabular fracture fixation via a modified Stoppa limited intrapelvic approach. Description of operative technique and preliminary treatment results. *Clinical Orthopaedics and Related Research* 1994;**305**:112–23.
48. Magill P, McGarry J, Queally JM, Morris SF, McElwain JP. Minimum ten-year follow-up of acetabular fracture fixation from the Irish tertiary referral centre. *Injury* 2012;**43**:500–4.
49. Meinhard BP, Misoul C, Joy D, Ghillani R. Central acetabular fracture with ipsilateral femoral-neck fracture and intrapelvic dislocation of the femoral head without major pelvic-column disruption. A case report. *The Journal of Bone and Joint Surgery American Volume* 1987;**69**:612–5.
50. Venerys JE, Nissen KI. Central fracture dislocation of right hip. *Proceedings of the Royal Society of Medicine* 1968;**61**:669–70.
51. Coley BL. Central fracture of the acetabulum: with report of a case. *The Journal of Bone and Joint Surgery American Volume* 1925;**7**:A:458–64.
52. Elliott PR. Unusual cause of central dislocation of the hip. *British Medical Journal* 1972;**3**:214.
53. Jostes FA. Fracture of the acetabulum with central dislocation of the head of the femur: a method of treatment. *The Journal of Bone and Joint Surgery American Volume* 1936;**18**:A:483–6.
54. Moore TM, Hill JV, Harvey Jr JP. Central acetabular fracture secondary to epileptic seizure. *The Journal of Bone and Joint Surgery American Volume* 1970;**52**:1459–62.
55. Sarpel Y, Togrul E, Herdem M, Tan I, Baytok G. Central acetabular fracture-dislocation following electroconvulsive therapy: report of two similar cases. *The Journal of Trauma* 1996;**41**:342–4.
56. Van Heest A, Vorlicky L, Thompson Jr RC. Bilateral central acetabular fracture dislocations secondary to sustained myoclonus. *Clinical Orthopaedics and Related Research* 1996;**324**:210–3.
57. Browne PS. Central dislocation of the hip with complications. *Injury* 1976;**8**:70–1.
58. Eastwood JB, Parker B, Reid BR. Bilateral central fracture-dislocation of hips after myelography with meglumine iocarmate (Dimmer X). *British Medical Journal* 1978;**1**:692–3.
59. Stewart MJ, Milford LW. Fracture-dislocation of the hip: an end-result study. *The Journal of Bone and Joint Surgery American Volume* 1954;**36**:315–42.
60. Kang CS, Min BW. Cable fixation in displaced fractures of the acetabulum: 21 patients followed for 2–8 years. *Acta Orthopaedica Scandinavica* 2002;**73**:619–24.
61. Mears DC, Shirahama M. Stabilization of an acetabular fracture with cables for acute total hip arthroplasty. *The Journal of Arthroplasty* 1998;**13**:104–7.
62. Archdeacon MT, Kazemi N, Guy P, Sagi HC. The modified Stoppa approach for acetabular fracture. *The Journal of the American Academy of Orthopaedic Surgeons* 2011;**19**:170–5.
63. Bellabarba C, Berger RA, Bentley CD, Quigley LR, Jacobs JJ, Rosenberg AG, et al. Cementless acetabular reconstruction after acetabular fracture. *The Journal of Bone and Joint Surgery American Volume* 2001;**83**:A:868–76.
64. Culemann U, Holstein JH, Kohler D, Tzioupis CC, Pizanis A, Tosounidis G, et al. Different stabilisation techniques for typical acetabular fractures in the elderly – a biomechanical assessment. *Injury* 2010;**41**:405–10.
65. Marintschev I, Gras F, Schwarz CE, Pohlemann T, Hofmann GO, Culemann U. Biomechanical comparison of different acetabular plate systems and constructs – the role of an infra-acetabular screw placement and use of locking plates. *Injury* 2012;**43**:470–4.
66. Hu Y, Li H, Qiao G, Liu H, Ji A, Ye F. Computer-assisted virtual surgical procedure for acetabular fractures based on real CT data. *Injury* 2011;**42**:1121–4.
67. Shahulhameed A, Roberts CS, Pomeroy CL, Acland RD, Giannoudis PV. Mapping the columns of the acetabulum – implications for percutaneous fixation. *Injury* 2010;**41**:339–42.
68. Ochs BG, Marintschev I, Hoyer H, Rolauffs B, Culemann U, Pohlemann T, et al. Changes in the treatment of acetabular fractures over 15 years: analysis of 1266 cases treated by the German Pelvic Multicentre Study Group (DAO/DGU). *Injury* 2010;**41**:839–51.
69. Geoghegan JM, Longdon EJ, Hassan K, Hahn DM, Calthorpe D. Acetabular surgical units: a directory for the United Kingdom. *Injury* 2010;**41**:677–9.
70. Liporace FA, Yoon RS, Frank MA, Maurer JP, Gaines RJ. Single-stage total hip arthroplasty and fracture fixation for a both column acetabular fracture in type I osteogenesis imperfecta. *Injury* 2011;**42**:1184–7.
71. Rommens PM, Ingelfinger P, Nowak TE, Kuhn S, Hessmann MH. Traumatic damage to the cartilage influences outcome of anatomically reduced acetabular fractures: a medium-term retrospective analysis. *Injury* 2011;**42**:1043–8.
72. Pantazopoulos T, Mousafiris C. Surgical treatment of central acetabular fractures. *Clinical Orthopaedics and Related Research* 1989;**246**:57–64.
73. Magu NK, Rohilla R, Arora S. Conservatively treated acetabular fractures: a retrospective analysis. *Indian Journal of Orthopaedics* 2012;**46**:36–45.
74. Hull JB, Raza SA, Stockley I, Elson RA. Surgical management of fractures of the acetabulum: the Sheffield experience 1976–1994. *Injury* 1997;**28**:35–40.
75. de Ridder VA, de Lange S, Kingma L, Hogervorst M. Results of 75 consecutive patients with an acetabular fracture. *Clinical Orthopaedics and Related Research* 1994;**305**:53–7.
76. Chiu FY, Chen CM, Lo WH. Surgical treatment of displaced acetabular fractures – 72 cases followed for 10 (6–14) years. *Injury* 2000;**31**:181–5.
77. Johnson EE, Matta JM, Mast JW, Letournel E. Delayed reconstruction of acetabular fractures 21–120 days following injury. *Clinical Orthopaedics and Related Research* 1994;**305**:20–30.
78. Alonso JE, Davila R, Bradley E. Extended iliofemoral versus triradiate approaches in management of associated acetabular fractures. *Clinical Orthopaedics and Related Research* 1994;**305**:81–7.
79. Griffin DB, Beaulieu PE, Matta JM. Safety and efficacy of the extended iliofemoral approach in the treatment of complex fractures of the acetabulum. *The Journal of Bone and Joint Surgery British Volume* 2005;**87**:1391–6.
80. Chang JK, Gill SS, Zura RD, Krause WR, Wang GJ. Comparative strength of three methods of fixation of transverse acetabular fractures. *Clinical Orthopaedics and Related Research* 2001;**392**:433–41.
81. Mears DC, Velyvis JH. Primary total hip arthroplasty after acetabular fracture. *Instructional Course Lectures* 2001;**50**:335–54.
82. Sermon A, Broos P, Vanderschot P. Total hip replacement for acetabular fractures. Results in 121 patients operated between 1983 and 2003. *Injury* 2008;**39**:914–21.
83. Mears DC, Velyvis JH. Acute total hip arthroplasty for selected displaced acetabular fractures: two to twelve-year results. *The Journal of Bone and Joint Surgery American Volume* 2002;**84**:A:1–9.
84. Mouhsine E, Garofalo R, Borens O, Blanc CH, Wettstein M, Leyvraz PF. Cable fixation and early total hip arthroplasty in the treatment of acetabular fractures in elderly patients. *The Journal of Arthroplasty* 2004;**19**:344–8.
85. Olive Jr RJ, Marsh HO. Occult central acetabular fracture resulting in fracture-dislocation. A case report. *Clinical Orthopaedics and Related Research* 1989;**248**:240–5.
86. Romness DW, Lewallen DG. Total hip arthroplasty after fracture of the acetabulum. Long-term results. *The Journal of Bone and Joint Surgery British Volume* 1990;**72**:761–4.
87. Weber M, Berry DJ, Harmsen WS. Total hip arthroplasty after operative treatment of an acetabular fracture. *The Journal of Bone and Joint Surgery American Volume* 1998;**80**:1295–305.
88. Lai O, Yang J, Shen B, Zhou Z, Kang P, Pei F. Midterm results of uncemented acetabular reconstruction for posttraumatic arthritis secondary to acetabular fracture. *The Journal of Arthroplasty* 2011;**26**:1008–13.
89. Schreurs BW, Zengerink M, Welten ML, van Kampen A, Slooff TJ. Bone impaction grafting and a cemented cup after acetabular fracture at 3–18 years. *Clinical Orthopaedics and Related Research* 2005;**437**:145–51.
90. Zhang L, Zhou Y, Li Y, Xu H, Guo X, Zhou Y. Total hip arthroplasty for failed treatment of acetabular fractures: a 5-year follow-up study. *The Journal of Arthroplasty* 2011;**26**:1189–93.
91. Ranawat A, Zelken J, Helfet D, Buly R. Total hip arthroplasty for posttraumatic arthritis after acetabular fracture. *The Journal of Arthroplasty* 2009;**24**:759–67.
92. Huo MH, Solberg BD, Zatorski LE, Keggi KJ. Total hip replacements done without cement after acetabular fractures: a 4- to 8-year follow-up study. *The Journal of Arthroplasty* 1999;**14**:827–31.
93. Berry DJ, Halasy M. Uncemented acetabular components for arthritis after acetabular fracture. *Clinical Orthopaedics and Related Research* 2002;**405**:164–7.