

Shotgun wound and pellet embolism to the intracranial carotid artery

Carlos Vaquero-Puerta, MD, Enrique M. San Norberto, MD, Borja Merino, MD, José A. González-Fajardo, MD, and James Taylor, MD, *Valladolid, Spain*

Missile embolism into the cerebral circulation is a very unusual complication of shotgun wounds to the chest or neck. We report a case of an 11-year-old boy who sustained an air gunshot wound and pellet embolism to the intracranial carotid artery. The cerebral artery pellet embolus resulted in contralateral hemiplegia. The patient was successfully treated by emergency flow reversal and embolectomy. Because this injury is extremely rare, the literature is reviewed, and several principles are suggested to improve the management. (*J Vasc Surg* 2012;55:535-7.)

Embolism of metallic missiles into the cerebral circulation is a very unusual event following a shotgun wound to the chest or neck.¹ They are generally projectiles of low velocity with delayed pellet embolization and fatal consequences. We report a case of an air gunshot wound and pellet embolism to the intracranial carotid artery that was successfully treated by flow reversal and embolectomy. Because this injury is extremely rare, the literature is reviewed, and several principles are suggested to improve the management.

CASE REPORT

An 11-year-old boy was shot accidentally with an air gun on the right side of the neck on zone 2. The patient did not show any neurologic deficit. There was a small entrance wound at the hypopharynx, but no exit wound could be found. Plain X-ray films revealed the presence of a pellet lodged within the neck close to the carotid artery. On the next day, a new fluoroscopy showed the pellet lodged within the skull just below the clinoid process on the right side (Fig 1), and the patient was quickly transferred to our vascular department. On admission in our center 3 hours later, the patient sustained a left hemiplegia with a positive Babinsky sign. He was immediately taken to the operating room, and under general anesthesia, the common, external, and internal carotid arteries were controlled. A single perforation of the anterior wall of the common carotid artery near the bifurcation was observed. After systemic heparinization, the arteriotomy was reopened at that point. A flow reversal technique was carried out by clamping the common and external carotid arteries while the internal carotid artery was yielded open. The systolic pressure was increased with noradrenalin (0.04-0.4 µg/kg/min, to increase the mean arterial pressure to 20-40 mm Hg), and the pellet was then expelled by

back flushing, and a small Fogarty catheter (n°3) was used to remove the presumed adherent thrombus (Fig 2). Under fluoroscopic guidance, it was passed only one time from the intracranial portion of the internal carotid artery before the Willis circle, and no thrombus was obtained. The passage of the embolectomy catheter should be carried out with great caution to avoid creating a carotid-cavernous sinus fistula. Passing the embolectomy catheter only up to the level of the skull base should avoid this serious complication. The pellet caliber was 4.5 mm. An intraoperative control angiogram was performed, and no secondary thrombus was detected. The arteriotomy was closed first, and the patient was taken to the intensive care unit where he recovered without any neurologic deficit on awakening from anesthesia. Postoperatively, the patient remained hemodynamically stable. A computed tomographic (CT) scan of the head was normal and no signs of brain damage were observed.

DISCUSSION

Although missile embolization into the intracranial arterial system is an extremely rare occurrence, it has already become something more than a surgical curiosity. In fact, 41 cases have been reported in the literature with usually fatal consequences (Table). Surgical intervention with the goal of pellet embolectomy^{2,3} has not really been performed in the intracranial circulation because of the small vessel size, the propensity for vasospasm, and the risk of iatrogenic damage.

With the exception of some metallic fragments,^{2,4,5} the majority of projectiles involved in these lesions have been shotgun pellets whose external entrance site was the neck or chest. These embolic missiles are of low velocity, and they don't have enough kinetic energy to pass completely through tissues.⁴ Although many times the site of penetration into the arterial system was not clearly identified, in the cases of neck injury^{2-4,6-11} the carotid artery was usually the point of penetration, although one case of vertebral artery was described.⁴ When the chest has been involved,^{1,2,4,5,11-13} the metallic foreign body is dislodged into the intracranial circulation through the aorta, supra-aortic vessels, left ventricle, or even the pulmonary veins. In these cases, the hemispheric site of embolization was primarily influenced by the anatomy of the arterial system. The pellet that ascends the aortic arch is more likely to enter the innomi-

From the Division of Angiology and Vascular Surgery, Valladolid University Hospital.

Competition of interest: none.

Reprint requests: Carlos Vaquero-Puerta, MD, Division of Vascular Surgery, Valladolid University Hospital, Valladolid, Spain, C/Ramón y Cajal n°3, 47005, Valladolid. Spain (e-mail: cvaquero@med.uva.es).

The editors and reviewers of this article have no relevant financial relationships to disclose per the JVS policy that requires reviewers to decline review of any manuscript for which they may have a competition of interest.

0741-5214/\$36.00

Copyright © 2012 by the Society for Vascular Surgery.

doi:10.1016/j.jvs.2011.07.091

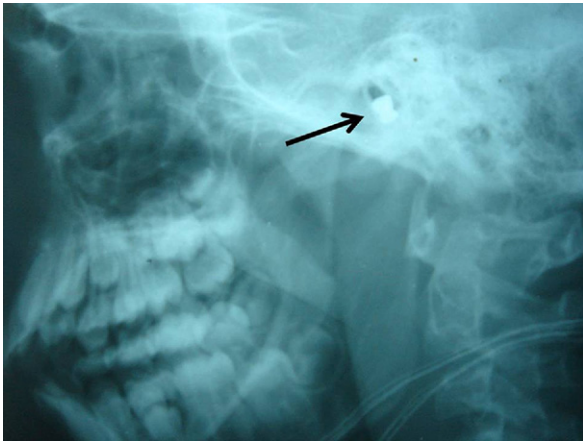


Fig 1. Plain X-rays showing the pellet within the skull just below the clinoid process (*arrow*).

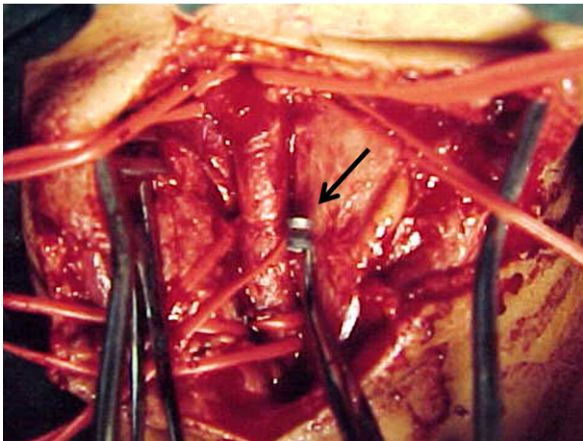


Fig 2. Intraoperative picture in which the pellet (*arrow*) is removed by internal carotid artery flow reversal.

nate artery because it is the first available branch. This fact explains that the right side of the brain was more frequently damaged.^{1-4,12,13} On the other hand, the small size and shape of the missile are factors that contribute to its retention into a particular location. In the majority of cases, they were lodged into the middle cerebral artery (73.8%),^{1,2,4-6,8-12} but in eight cases they were in some portion of the internal carotid artery because the vessel restricted the migration (ie, air gunshot).^{2,4,13}

Generally, the missile embolism takes place with some delay (hours, days, or even months) after admission into the hospital.⁴ This delayed cerebral embolization was sometimes due to maneuvers of cardiac resuscitation, attempts of withdrawal, or migration due to progressive arterial wall erosion from the pulmonary veins or ventricles.^{1,5,6} In two facilities, the injury was discovered at necropsy.^{4,12} In cases of children with an injury from an air gun, the physician needs to have a heightened awareness that innocuous appearing entry wounds could be deep, penetrating, and

lethal.² In this type of lesion, at the time of the lesion, plain X-rays are essential to localize the pellets.⁴ Despite the metallic density of the foreign body producing artefacts, a CT is important to assess tissue damage and to plan a surgical approach.^{4,6} The role of arteriography remains controversial. This procedure may be necessary to identify the location of the embolus and the cerebral collateral flow,⁴ but in cases (coma, hemiplegia) where surgery was required, unnecessary delay should be avoided. It could be indicated after minor neurologic impairment (aphasia, monoparesis).

Neurologic symptoms have been diverse and included initial coma,^{2,4,12} hemiplegia,^{1,2,4,9} hemiparesis,^{2,4,5,7,10,11} aphasia,^{2,4,10} monoparesis,⁴ and quadrantanopsia.³ However, seven patients were asymptomatic,^{2,4,6,9,13} probably because the collateral flow from the opposite side or partial instead of complete occlusion of the involved artery avoided a cerebral infarction.

The optimal management is not clear. In our collected series of 42 patients, 12 patients (28.7%) underwent surgery,^{2-4,8,9,13} and 30 (73.3%) underwent conservative treatment.^{1,2,4,5-7,10-12} Eleven patients^{2,4,12} with neurologic deficit that were not taken to surgery died (36.7%). Of the patients surgically treated, the missile was successfully removed in 11 cases (six by neurosurgery and five by embolectomies). In one case, the pellet migrated to a distal vessel during surgical manipulation (angular artery), and the patient developed a permanent quadrantanopsia.³ In another case, it was pushed to a more distal branch.² Although the surgical indication for removing a metallic foreign body is classically based on the necessity of reestablishing cerebral flow avoiding the risk of infection and vascular erosion,⁴ these later complications have never been reported. Indeed, the missile was left in place in 30 cases, four (13.4%) asymptomatic patients,^{2,4,6} and 26 (86.6%) with some neurologic deficit.^{1,2,4,5,7,10-12} So, in opposition to the peripheral vessels, the intracranial pellets usually are well tolerated if the patient survives the injury.

Significant penetrating carotid artery injuries without concurrent central neurologic deficit should be repaired. Nevertheless, optimal neurologic outcomes are obtained with operative repair in cases of carotid injuries associated with neurologic deficit. Carotid repair in asymptomatic patients with occlusion of the carotid artery should be performed when it is technically feasible and when retrograde arterial backflow can be established. Nonoperative management appears to be safe in neurologically intact patients with minor carotid artery injuries (small intimal defects or small pseudoaneurysms), but serial carotid duplex ultrasound and close clinical follow-up also seem mandatory. Anticoagulation should be considered for traumatic distal internal carotid artery occlusion in neurologically intact patients.

In conclusion, we recommend the technique of flow reversal, particularly when the pellet is placed in the intracranial portion of the internal carotid artery before the Willis circle and the back flushing can dislodge it. In cases in

Table. Reported cases of cerebral embolization of metallic missiles in the literature

Artery/site	Cases	References	Surgery	Outcome
Middle cerebral artery	31	1, 2, 4-6, 8-12	22 no 6 neurosurgery 3 embolectomy	8 death 7 asymptomatic 16 neurologic deficit
Intracranial internal carotid artery	8	Current case 2, 4, 13	No	2 death 4 asymptomatic 2 neurologic deficit
Posterior cerebral artery	1	4	No	Death
Angular artery	1	3	Embolectomy	Quadrantanopsia
Anterior cerebral artery	1	7	No	Hemiparesis

which the missile was placed into the middle cerebral artery or other distal branch, the prognosis could be worse and an expectant attitude is recommended. A conservative treatment is recommended in cases of distal embolization or important injuries associated.

REFERENCES

- Bahnini A, Petitjean C, Kieffer E. Gunshot pellet embolus to the middle cerebral artery. *Ann Vasc Surg* 1986;1:139-42.
- Dadsetan MR, Jinkins JR. Peripheral vascular gunshot bullet embolus migration to the cerebral circulation. Report and literature review. *Neuroradiology* 1990;32:516-9.
- Anda T, Suyama K, Kawano T, Mori K. Shotgun pellet embolus in the cerebral circulation via the internal carotid artery in the neck: a case report. *No Shinkei Geka* 1992;20:457-61.
- Oser AB, Moran CJ, Cross DWT, Thompson RW. Shotgun pellet embolization to the intracranial internal carotid artery: report of a case and review of the literature. *Emerg Radiol* 1994;1:200-5.
- Stein M, Mirvis SE, Wiles CE. Delayed embolization of a shotgun pellet from the chest to the middle cerebral artery. *J Trauma* 1995;39:1006-9.
- Cogbill TH, Sullivan HG. Carotid artery pseudoaneurysm and pellet embolism to the middle cerebral artery following a shotgun wound of the neck. *J Trauma* 1995;39:763-7.
- van As AB, Pillay R, Domingo Z. Shotgun pellet embolus to the anterior cerebral artery. *Injury* 1995;26:631-2.
- Haninec P, Houstava L, Klener J. Shotgun pellet embolus of the middle cerebral artery treated by emergency embolectomy. *Br J Neurosurg* 1996;10:311-4.
- Song JK, Srinivasan J, Gordon DS, Newell DW, Baxter AB. Internal carotid pseudoaneurysm and cerebral infarction from shotgun pellet penetration and embolization. *AJR Am J Roentgenol* 1999;173:1116.
- Yaari R, Ahmadi J, Chang GY. NeuroImages. Cerebral shotgun pellet embolism. *Neurology* 2000;54:1487.
- David W, Odeh Y, Mittal V. Shotgun pellet embolus to the middle cerebral artery: case report. *J Trauma* 2003;54:417.
- Dada MA, Loftus IA, Rutherford GS. Shotgun pellet embolism to the brain. *Am J Forensic Med Pathol* 1993;14:58-60.
- Pacio CI, Murphy MA. BB embolus causing monocular blindness in a 9-year-old boy. *Am J Ophthalmol* 2002;134:776-8.

Submitted Jun 16, 2011; accepted Jul 18, 2011.