


Review Article

Complications associated with the use of silicone oil in vitreoretinal surgery: A systemic review and meta-analysis

Fco. Javier Valentín-Bravo,^{1,2} Luis García-Onrubia,¹ Cristina Andrés-Iglesias,² Eduardo Valentín-Bravo,³ Javier Martín-Vallejo,⁴  José Carlos Pastor,^{1,2,3,5} Ricardo Usategui-Martín^{2,3,5} and Salvador Pastor-Idoate^{1,2,3,5} 

¹Department of Ophthalmology, University Clinical Hospital of Valladolid, Valladolid, Spain

²Institute of Applied Ophthalmobiology (IOBA), University of Valladolid, Valladolid, Spain

³Medical School, University of Valladolid, Valladolid, Spain

⁴Department of Statistics, Medical School, University of Salamanca. Salamanca Biomedical Research Institute (IBSAL), Salamanca, Spain

⁵Cooperative Network for Research in Ophthalmology (Oftared), Carlos III National Institute of Health, ISCIII, Madrid, Spain

ABSTRACT.

Silicone oil (SO) still represents the main choice for long-term intraocular tamponade in complicated vitreoretinal surgery. This review compared the complications associated with the use of SO and other vitreous substitutes after pars plana vitrectomy in patients with different underlying diseases. Meta-analysis was conducted in accordance with PRISMA guidelines. We retrieved randomized clinical trials (RCTs), retrospective case-control and cohort studies evaluating the risk of using SO, published between 1994 and 2020, conducting a computer-based search of the following databases: PubMed, Web of Science, Scopus and Embase. Primary outcome was the rate of complications such as intraocular hypertension, retinal re-detachment, unexpected vision loss or hypotony. Secondary outcome was to compare the rate of adverse events of different SO viscosities, especially emulsification. Forty-three articles were included. There were significant differences in intraocular hypertension ($p = 0.0002$, OR = 1.66; 95% CI = 1.27–2.18) and the rate of retinal re-detachment ($p < 0.0009$, OR = 0.65; 95% CI = 0.50–0.64) between SO and other agents, including placebo. However, there were no differences in other complication rates. Silicone oil (SO)-emulsification rate was non-significantly higher in low than high SO viscosity, and results from other complications were comparable in both groups. The high quality of most of the studies included in this study is noteworthy, which provides some certainty to the conclusions. Among them is the high variability of the SO residence time. The fact that ocular hypertension and not hypotension is related to SO use. A clear relationship is not found for the so-called unexplained vision loss, which affects a significant percentage of eyes. Re-detachment cases are less if SO is used and that surprisingly there does not seem to be a relationship in the percentage of emulsification between the low- and high-viscosity silicones. All these data warrant more standardized prospective studies.

Key words: complications – intraocular tamponade and pars plana vitrectomy – Silicone oil – vitreous substitute

The authors thank the researchers of the primary studies identified for this meta-analysis.

The above information has not been presented previously in any meeting. The author CAI receives funding from AJL Ophthalmic S.A. The authors JCP and CAI are members of the ISO Technical Committee involved in ISO 16672:2020 ‘Ophthalmic Implants–Ocular endotamponades’. Author JCP is also vice-chair of the Expanded Committee of the European Union for ‘ocular medical devices’.

Acta Ophthalmol.

© 2021 The Authors. Acta Ophthalmologica published by John Wiley & Sons Ltd on behalf of Acta Ophthalmologica Scandinavica Foundation

This is an open access article under the terms of the Creative Commons Attribution-NonCommercial-NoDerivs License, which permits use and distribution in any medium, provided the original work is properly cited, the use is non-commercial and no modifications or adaptations are made.

doi: 10.1111/aos.15055

Introduction

Silicone oil (SO) (polydimethylsiloxane) is a liquid synthetic hydrophobic polymer composed of repeating units of siloxane and oxygen bonds (Kleinberg et al. 2011; Ni et al. 2019). This polymer is of ophthalmological interest as a vitreous substitute, and it was firstly introduced into vitreoretinal surgery by Cibis et al. (1962), by its properties. Silicone oil (SO) is chemically inert, stable for an extended period of time, with a specific gravity (slightly less than water), transparent, with a refractive index similar to that of the vitreous and easy to remove with high surface tension and viscosity (Alovisi et al. 2017; Ni et al. 2019). For these reasons, SO has been widely accepted as a long-term vitreous replacement after pars plana vitrectomy (PPV) for the last 50 years (Cibis et al. 1962; Kleinberg et al. 2011; Alovisi et al. 2017; Feng et al. 2017; Ni et al. 2019).

Although the use of SO is widely accepted for complicated vitreoretinal cases such as those with proliferative vitreoretinopathy (PVR), tractional retinal detachment (RD), severe cases of diabetic retinopathy, repair of giant retinal tears, ocular trauma and perforating injuries, and less commonly acute retinal necrosis, endophthalmitis

and hypotony (Schwartz et al. 2014), the efficacy of SO after PPV is limited by the occurrence of several complications mainly emulsification, which can lead to postoperative anterior segment problems, particularly secondary glaucoma, cataract and keratopathy (Toklu et al. 2012; Miller et al. 2014; Alovisei et al. 2017; Feng et al. 2017; Abu-Yaghi et al. 2020), and also, with the possibility of having the so named silicone retinotoxicity with reported cases of central visual loss, decreased choroidal thickness, subretinal and even intracranial migration (Toklu et al. 2012; Miller et al. 2014; Grzybowski & Ascaso 2016; Alovisei et al. 2017; Feng et al. 2017; Ni et al. 2019; Abu-Yaghi et al. 2020). Silicone oil (SO) is strongly lipophilic, and it is capable of dissolving the lipids of the cell membranes inside the eye, with which its long-term toxicity seems out of the question (Pastor Jimeno et al. 2007). Furthermore, even the appearance of anti-SO antibodies in patients with SO implants after RD surgery has been reported (Carlos Pastor et al. 2001).

Therefore, the removal of SO (ROSO) is usually recommended as soon as possible to avoid or reverse these complications (Ni et al. 2019; Abu-Yaghi et al. 2020). However, in certain cases, ROSO is also associated with complications including recurrent RD and hypotony (Issa et al. 2020). Typically, recommendations range from 3 to 6 months of its placement. However, there is still no consensus about the optimal silicone removal time and the decision of maintaining SO for a longer period of time depends on several factors such as unsatisfactory retinal reattachment (RRD), the elevation of intraocular pressure or lens status. One of the major reasons for the absence of definitive agreement is the lack of knowledge about *in vivo* emulsification process of SO intraocularly and its variations among patients (Ni et al. 2019). In fact, some clinicians have shown that prolonged SO tamponade does not increase those risks significantly (Pavlovic et al. 1995; Lam et al. 2008; Rhatigan et al. 2018).

Although it has been reported that the use of other intraocular tamponades such as perfluoropropane (C₃F₈) or hexafluoroethane (C₂F₆) could be reasonable choices for patients with complicated RD (Schwartz et al. 2014; Banerjee et al. 2017; Neffendorf et al. 2018), they can also lead to postoperative complications. Studies assessing

the outcomes of long-term SO and specifically comparing the extended complications and outcomes between other vitreous tamponades and SO are currently limited, and the published results are not in accordance with a variety of limitations and different methods. Therefore, we have conducted a systematic review and meta-analysis to summarize the data extracted from including studies with the aim to analyse the clinical complications associated with the use of SO. This may be useful for surgeons to decide among different tamponades agents used in complex RD surgery and provide precautions for patients with higher risks.

Materials and methods

Search strategy

This systematic review and meta-analysis was conducted in accordance with the PRISMA guidelines (Moher et al. 2009). We retrieved randomized clinical trials, retrospective case-control and cohort studies evaluating the risk of SO published between 1994 and 2020. To identify eligible studies, we conducted computer-based searches of the following databases: PubMed, Web of Science, Scopus and Embase electronic databases. Bibliographic research was conducted by two independent reviewers (FJVB and LGO). Combinations of the following search with Medical Subject Headings (MeSH) terms were used to identify potentially relevant articles: 'Silicone oil complications', 'comparison silicone oil', 'silicone oil versus gas', 'giant retinal tear', 'retinal re-detachment', 'ocular hypertension', 'migration', 'vision loss', 'emulsification', 'inflammation', 'anterior chamber', 'keratopathy', 'macular hole', 'epiretinal membrane' and 'cataract'. The search was performed between 1994, when FDA approved SO for the purpose of intraocular tamponade, and November 2020. The language was restricted to English, and the search was supplemented using the Medline option 'Related Articles' and consulting review articles on the topic. Any disagreements were resolved through discussion.

Selection criteria

The full texts of potentially relevant articles were reviewed to identify studies that met the inclusion and exclusion

criteria. For the primary outcome, the articles were considered eligible if they are based on case-control or cohort studies and RCTs comparing the outcomes and evaluating the risk of SO versus other vitreous tamponades such as air, sulphur hexafluoride (SF₆), hexafluoroethane (C₂F₆), octafluoropropane (C₃F₈), heavy SO or others. For the secondary outcome, only studies comparing the risk of high (5000 cst) vs low (1000–2000 cst) viscosity SOs were considered eligible. Studies with overlapping data were excluded (only the study with the largest population was included). The clinical complications included in the systematic review and meta-analysis were ocular hypertension (OHT), PVR, RRD, emulsification, macular pucker or epiretinal membrane (ERM), corneal decompensation, unexplained vision loss, hypotony and/or cataract. Non-comparative studies were excluded, as well as editorials, expert opinions, letters to the editor and case reports. Any disagreements were resolved by consensus between the investigators.

Quality assessment

Two reviewers independently rated the quality of each case-control or cohort studies by assessing its methodology with the Newcastle-Ottawa Quality Assessment Scale (NOS) (Stang 2010). Three main parameters are assessed to evaluate each study's quality, including patient selection, comparability of the study groups and outcome assessment. A star system is used to qualify the studies with a maximum of 9 stars. Study quality was ranked as high, moderate or low (score categories 7–9, 4–6 and 0–3, respectively). The risk of bias of each RCTs was assessed with the Cochrane Collaboration's tool ("Cochrane Handbook for Systematic Reviews of Interventions | Cochrane Training" n.d.). Study quality was ranked as low, high and unclear risk of bias. Any discrepancy was resolved through discussion.

Data extraction

Two authors (FJVB and LGO) independently extracted and summarized the relevant characteristics of each eligible study. The searches for titles and abstracts were executed electronically, and records were managed by

Microsoft Excel software[®]. Data extracted the following information for each publication: the author's name, date of publication, country, age and gender of case and control subjects, number of participants, type of vitreous substitutes and the complications reported. Then, outcomes were extracted from the data. The outcomes were related the final follow-up examination in each study. The primary outcome was the adverse events (e.g. retinal re-detachment, PVR, ERM...) associated with the use of SO in complex retinal surgeries compared to other vitreous tamponades in both observational and RTCs studies. The secondary outcome was the analysis of complications between the use of high- and low-viscosity SOs as vitreous tamponade and the rate of emulsification between them. The comparisons among different outcomes in this meta-analysis were only made when three or more studies were available. Disagreements or discrepancies between reviewers regarding data extraction were resolved with the senior investigators (RUM and SPI).

Statistical analysis

Random-effects model was applied to calculate the odds ratio (OR) and its 95% confidence interval (CI). Statistical significance was considered with p -value < 0.05 . The between-study variance was estimated by DerSimonian & Laird method (DerSimonian & Laird 1986). Q statistic was used to evaluate heterogeneity. The significance level chosen to declare heterogeneity was 0.10 given the low power of this test (Hardy & Thompson 1998). Besides I^2 was calculated to evaluate the magnitude of heterogeneity (Grant & Hunter 2006). Funnel plot and Begg's test were used to assess publication bias. Sensitivity analysis was performed by excluding individual studies. The meta-analysis was performed using RevMan 5.0 software (Review Manager (RevMan) [Computer Program] 2014).

Results

Selection of relevant studies

Forty-three eligible articles were included in the final analysis. For the primary outcome, 35 eligible articles

met the inclusion criteria (Pertile & Claes 1999; Kapran et al. 2001; Tabandeh et al. 2000; Lu et al. 2002; Schmidt et al. 2003; Tafoya et al. 2003; Ghosh et al. 2004; Yang et al. 2008; Wong et al. 2009; Romano et al. 2010; Mete et al. 2011; Christensen & La Cour 2012; Kocak & Koc 2013; Caiado et al. 2015; Lumi et al. 2016; Scheerlinck et al. 2016; Fang et al. 2017; Lee et al. 2018; Cankurtaran et al. 2017; Rodriguez et al. 2018; Semeraro et al. 2019; Lyssek-Boroń et al. 2019; Hammer et al. 1997; Batman & Cekic 1999; Do et al. 2014; Azad et al. 2003; Nagpal et al. 2012; Boscia et al. 2008; Joussem et al. 2011; Teresio Avitabile et al. 2011; Joussem et al. 2011; Nagpal et al. 2012; Do et al. 2014; Kakinoki et al. 2019; Moharram et al. 2020; Banerjee et al. 2017; Murat n.d.). Of these, 26 articles reporting on case-control and cohort studies (Banerjee et al. 2017; Pertile & Claes 1999; Kapran et al. 2001; Tabandeh et al. 2000; Lu et al. 2002; Schmidt et al. 2003; Ghosh et al. 2004; Yang et al. 2008; Wong et al. 2009; Romano et al. 2010; Mete et al. 2011; Christensen & La Cour 2012; Kocak & Koc 2013; Caiado et al. 2015; Lumi et al. 2016; Scheerlinck et al. 2016; Fang

et al. 2017; Lee et al. 2018; Cankurtaran et al. 2017; Rodriguez et al. 2018; Scheerlinck et al. 2018; Semeraro et al. 2019; Lyssek-Boroń et al. 2019; Moharram et al. 2020; Kakinoki et al. 2019; Murat n.d.) and eight articles reporting on 8 RCTs (Hammer et al. 1997; Batman & Cekic 1999; Do et al. 2014; Azad et al. 2003; Nagpal et al. 2012; Boscia et al. 2008; Joussem et al. 2011; Teresio Avitabile et al. 2011) were included. For the secondary outcome, only eight eligible articles met the inclusion and were included for the analysis. Of these, six articles (Valone & McCarthy 1994; Davis et al. 1995; Scott et al. 2005; Soheilian et al. 2006; Oh et al. 2015; Yaşa & Alkın 2018) reporting on cohort, case-control studies and two articles reporting on two RCTs (Zafar et al. 2016; Ratana-pakorn et al. 2020) were included. Figure 1 summarizes the detailed flow diagram of the study identification process. The included studies were published from 1994 (FDA approved SO as intraocular tamponade) to 2020. Finally, this systematic review and meta-analysis included 4783 patients (4854 eyes). In 2379 patients (2392 eyes) from 21 articles, the eyes were

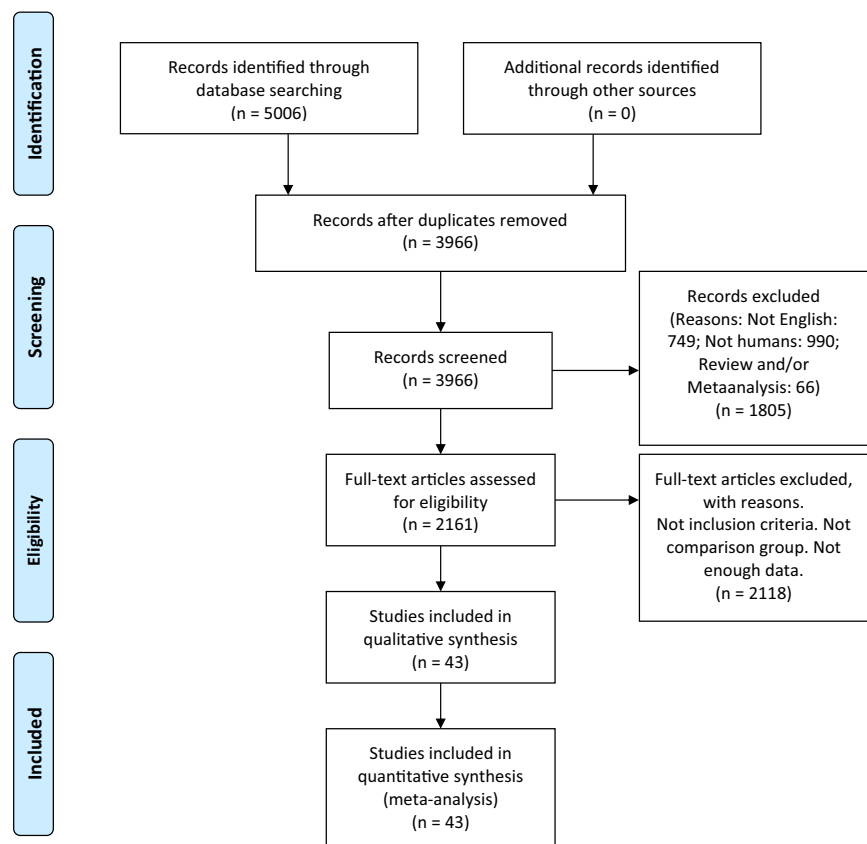


Fig. 1. Flow chart of the selection of studies for inclusion in the meta-analysis.

filled with SO or gases: (Hammer et al. 1997; Batman & Cekic 1999; Pertile & Claes 1999; Tabandeh et al. 2000; Kapran et al. 2001; Lu et al. 2002; Schmidt et al. 2003; Tafoya et al. 2003; Ghosh et al. 2004; Yang et al. 2008; Christensen & La Cour 2012; Do et al. 2014; Caiado et al. 2015; Lumi et al. 2016; Scheerlinck et al. 2016; Banerjee et al. 2017; Cankurtaran et al. 2017; Lee et al. 2018; Rodriguez et al. 2018; Scheerlinck et al. 2018; Moharram et al. 2020).

Supporting information: (Soheilian et al. 2006; Romano et al. 2010; Mete et al. 2011; Christensen & La Cour 2012; Kocak & Koc 2013; Lumi et al. 2016; Lee et al. 2018; Cankurtaran et al. 2017; Lyssek-Boroń et al. 2019; Yaşa & Alkın 2018; Davis et al. 1995; Valone & McCarthy 1994; Oh et al. 2015; Caiado et al. 2015; Scott et al. 2005; Fang et al. 2017; Rodriguez et al. 2018; Kakinoki et al. 2019; Moharram et al. 2020; Tabandeh et al. 2000; Schmidt et al. 2003; Lu et al. 2002; Murat n.d.), in 715 patients (715 eyes) from five articles, the eye was filled with SO or placebo (Azad et al. 2003; Nagpal et al. 2012; Fang et al. 2017; Kakinoki et al. 2019; Lyssek-Boroń et al. 2019); in 634 patients (634 eyes) from nine articles, the eye was filled with SO or heavy SO (Wong et al. 2009; Romano et al. 2010; Mete et al. 2011; Kocak & Koc 2013; Semeraro et al. 2019; Boscia et al. 2008; Joussem et al. 2011; Teresio Avitabile et al. 2011; Murat n.d.) and for the secondary outcome, 1055 patients (1113 eyes) from eight articles (Valone & McCarthy 1994; Davis et al. 1995; Scott et al. 2005; Soheilian et al. 2006; Oh et al. 2015; Zafar et al. 2016; Yaşa & Alkın 2018; Ratanapakorn et al. 2020) the eyes were filled with SO 1000, 2000 cst or 5000 cst.

Quality assessment and risk of bias

Case-control and cohort studies have a reasonable methodological quality, since 10 studies were ranked as moderate quality (Wong et al. 2009; Scheerlinck et al. 2018; Banerjee et al. 2017; Semeraro et al. 2019; Scheerlinck et al. 2016; Kapran et al. 2001; Ghosh et al. 2004; Yang et al. 2008; Pertile & Claes 1999; Tafoya et al. 2003), and 23 were classified as high quality (Soheilian et al. 2006; Romano et al. 2010; Mete et al. 2011; Christensen & La Cour

2012; Kocak & Koc 2013; Lumi et al. 2016; Lee et al. 2018; Cankurtaran et al. 2017; Lyssek-Boroń et al. 2019; Yaşa & Alkın 2018; Davis et al. 1995; Valone & McCarthy 1994; Oh et al. 2015; Caiado et al. 2015; Scott et al. 2005; Fang et al. 2017; Rodriguez et al. 2018; Kakinoki et al. 2019; Moharram et al. 2020; Tabandeh et al. 2000; Schmidt et al. 2003; Lu et al. 2002; Murat n.d.) with scores of 7 and over based on NOS. Of note, we decided to evaluate the outcome category taking into account if the follow-up time was long enough to detect the included outcomes. Therefore, investigations in which the intraocular pressure was evaluated were awarded a start if the follow-up time was at least 6 months after the last surgical intervention. In contrast, studies assessing visual acuity or retinal re-detachment were awarded a start if the follow-up time was at least 2 months after the last surgical intervention. Regarding the risk of bias (selection bias, attrition bias, and other bias), all the included studies reporting on RCTs had a low risk. For allocation concealment, the majority of studies (Hammer et al. 1997; Azad et al. 2003; Teresio Avitabile et al. 2011; Joussem et al. 2011; Nagpal et al. 2012; Do et al. 2014; Zafar et al. 2016; Ratanapakorn et al. 2020) were rated as low risk. However, the study made by Batman and Cekic (Batman & Cekic 1999) was ranked as an unclear risk since the method of concealment is not described in sufficient detail to permit a definitive judgment, and the investigation by Boscia et al. (2008), in which the patients were alternatively assigned, was ranked as high risk. Since surgeons can rarely be blinded in studies with different tamponades, we rated the performance bias as unclear (Hammer et al. 1997; Batman & Cekic 1999; Joussem et al. 2011; Nagpal et al. 2012; Do et al. 2014; Zafar et al. 2016) or high risk (Azad et al. 2003; Boscia et al. 2008; Teresio Avitabile et al. 2011). However, Ratanapakorn et al. (2020) incorporated an alternative blinding technique in which neither did surgeons nor researchers know the viscosity of SO used, unblinding it at the end of the study. Three trials were rated as low risk (Azad et al. 2003; Teresio Avitabile et al. 2011; Ratanapakorn et al. 2020) of detection bias, as they had masked outcome assessors, while the others were rated as unclear risk (Hammer

et al. 1997; Batman & Cekic 1999; Boscia et al. 2008; Joussem et al. 2011; Nagpal et al. 2012; Do et al. 2014; Zafar et al. 2016). For reporting bias (Hammer et al. 1997; Batman & Cekic 1999; Azad et al. 2003; Boscia et al. 2008; Teresio Avitabile et al. 2011; Nagpal et al. 2012; Do et al. 2014; Zafar et al. 2016; Ratanapakorn et al. 2020) it was rated as low risk in all included RCTs, except for one study (Joussem et al. 2011) rated as a high risk for lack of data. Details of the methodological quality of the included case-control and cohort studies and the risk of bias assessment of the 10 RCTs are provided in Tables S1 and S2.

Study characteristics and outcomes

The details of the included patients, retinal conditions before surgery and interventions are provided in Table 1. The vitreoretinal diseases included in this meta-analysis are summarized in Table S3. The number of eyes enrolled per study ranged from 11 to 677, with a median of 70. The mean age of the subjects included was 52.51 ± 14.01 years with a range from 0 to 90 years. The studies showed a higher prevalence of men than women (59.65% versus 40.35%). However, seven articles did not report the age or the sex of the subjects (Valone & McCarthy 1994; Hammer et al. 1997; Tabandeh et al. 2000; Christensen & La Cour 2012; Lee et al. 2018; Lyssek-Boroń et al. 2019; Murat n.d.). The mean duration follow-up time after surgery was 15.47 ± 13.52 months (median: 12; range: [1–120]). Only six articles did not specify the follow-up time (Davis et al. 1995; Schmidt et al. 2003; Oh et al. 2015; Lee et al. 2018; Kakinoki et al. 2019; Semeraro et al. 2019). The mean duration time before the ROSO was only detailed in 19 studies (Ghosh et al. 2004; Soheilian et al. 2006; Boscia et al. 2008; Romano et al. 2010; Mete et al. 2011; Nagpal et al. 2012; Christensen & La Cour 2012; Do et al. 2014; Oh et al. 2015; Zafar et al. 2016; Scheerlinck et al. 2016; Banerjee et al. 2017; Lee et al. 2018; Cankurtaran et al. 2017; Yaşa & Alkın 2018; Semeraro et al. 2019; Scheerlinck et al. 2018; Lyssek-Boroń et al. 2019; Murat n.d.), and it was 4.35 ± 3 months (median: 3.15 months; range 2–45.98). The 54.67% ($n = 1461$) of the eyes included in the meta-analysis

Table 1. General characteristics of the studies included in the meta-analysis.

Study	Country	Subject group	N	Age, year	Sex (F/M)	Tamponade, months	Follow-up, months	Phakia/pseudophakia/aphakia
Valone et al. (1994)	UK	Silicone oil 1000 cst	8	47.6 ± 20.0			33.2 ± 14.4	28/20
Davis et al. (1995)	USA	Silicone oil 5000 cst	40	47.6 ± 20.0			33.2 ± 14.4	
		Silicone oil 1000 cst	286	40	30/320			258/7/12
Hammer et al. (1997)	USA	Silicone Oil	121					100/9/6
		SF ₆	18	62.9 (23–82)			6	
Batman & Cekic (1999)	Turkey	Silicone Oil	25	45 (18–73)	8/17		48–60	
		C ₃ F ₈	22	40 (15–62)	6/16		60	
Pertile et al. (1999)	Netherlands	Silicone Oil	35	66 (54–76)	41/11		6.2 (3–13)	
		SF ₆	19				13.7 (5–19)	
Kapran et al. (2001)	Turkey	Silicone Oil	40	51.2 (±7.7) (15–78)	27/34		7 (4–24)	
		C ₃ F ₈ or other	21				7 (4–24)	
Tabandeh et al. (2000)	UK	Silicone Oil	7	60.9 ± 13.8 (38–80)			7.5 (2–24)	
		Gas	4				7.5 (2–24)	
Lu et al. (2002)	China	Silicone Oil	7	54.3 ± 7.6	5/2		27.6	
		Gas	58	52.1 ± 14.8	49/9		27.6	
Schmidt et al. (2003)	Germany	Silicone Oil	129	54 (18–84)	67/137			
		Gas	76					
Azad et al. (2003)	India	Silicone Oil	12	13.66 ± 6.82	2/22		10.08 ± 3.70	
		Placebo	12	10.08 ± 3.70			13.66 ± 6.82	
Tafoya et al. (2003)	USA	Silicone oil 5000 cst	21	66 (62–72)	15/6		11.8	11/0/10
		C ₃ F ₈ 14%	45	64 (61–70)	29/16		11.8	28/0/17
Ghosh et al. (2004)	UK	Silicone Oil	28	35.05 (7–60)	24/5	2–10	5–84	23/5/01
		C ₃ F ₈ 16%	1					
Scott et al. (2005)	USA	Silicone Oil 1000 cst	82	53.3 (5–86)	45/37		1–12	42/29/11
		Silicone Oil 5000 cst	243	55 (0–93)	153/90			131/78/34
Murat (n.d.)	Turkey	Silicone Oil	24			3.16 (2–6)	6–13	
		HSO (Densiron)	21					
Soheilian et al. (2006)	Iran	Silicone Oil 1000 cst	29		30/52	10 ± 6.5	4 to 120	0/0/82
		Control 5000 cst	53			23.9 ± 15.1	4 to 120	
Yang et al. (2008)	Taiwan	Silicone Oil 5000 cst	23	54.7 (25–70)	13/10		6	21/2
		C ₃ F ₈	17		12/15		6	14/3
Boscia et al. (2008)	Italy	Silicone Oil 1300 cst	10	59.6 ± 10.7	3/7	3	6	3/7
		HSO	10	65.3 ± 9.5	3/7	3	6	4/6
Wong et al. (2009)	UK	Silicone Oil	57	54.8 ± 18.4 (15–81)	20/37		1	25/25/7
		HSO (Densiron-68)	71	58.1 ± 17.9 (13–87)	29/42		1	29/37/5
Romano et al. (2010)	Italy	Silicone Oil	105	64 ± 21 (15–81)	73/34	6	12	65/35/5
		HSO (Densiron-68)	75	58 ± 15 (13–90)	30/45	3	12	57/15/3
Metete et al. (2011)	Italy	Silicone Oil	17	60.4 ± 10.1	31/10	2–4	12	
		HSO	25	64.6 ± 11.3		2–4	12	
Joussen et al. (2011)	Germany	Silicone Oil	47	61.87 ± 15.69	28/19		12	18/27/2
		HSO	46	65.54 ± 12.20	11/35		12	19/23/4
Avitaible et al. (2011)	Italy	Silicone Oil	15	64 (42–79)	8/7		6	6/9
		HSO (Densiron)	15	60 (40–77)	9/6		6	9/6
Nagpal et al. (2012)	India	Silicone Oil	64	40 (6–81)	15/49	6	6	16
		Placebo	65	42.5 (6–80)	21/44	6	6	15
Christensen et al. (2012)	Denmark	Silicone Oil 5500 cst	162	51 (33–69)		4.83(3.1–10.2)	46 (34–58)	
		C ₃ F ₈	54	62 (47–72)			51 (35–70)	
Kocak et al. (2013)	Turkey	Silicone Oil 1000 cst	30	56 ± 15.6	11/19			13/15/2
		HSO	31	57.9 ± 14.6	12/19			15/11/5
Do et al. (2014)	Vietnam	Silicone Oil	55	32.64 ± 16.72 (3–64)	22/33	3	9	
		SF ₆ or Placebo	53	31.72 ± 14.92 (8–69)	18/35		9	
Oh et al. (2015)	South Korea	Silicone Oil 1000 cst	17	49.05 ± 22.86	6/11	10.53 ± 7.50		1/14/2
		Silicone Oil 5700 cst	5	49.80 ± 10.04	1/4	26.89 ± 7.30		0/5/0
Caiado et al. (2015)	Brazil	Silicone Oil	32		14/18		6	7/25/0
		C ₃ F ₈ 15%	65		31/54		6	21/44/0
Zafar et al. (2016)	Pakistan	Silicone Oil 1000 cst	44		33/52	44.43 ± 16.8	18	
		Silicone Oil 5000 cst	41			45.98 ± 15.6		
Scheerlinck et al. (2016)	Netherlands	Silicone Oil	44	59 (36–82)	11/33	4	1.83 (0–3)	2/35/0
		C ₃ F ₈ , SF ₆ , air	151	60 (32–83)	63/88		1.73 (0–5.16)	65/85/1
Lumi et al. (2016)	Slovenia	Silicone Oil 2000 cst	28	61.15 ± 13.65	8/20		12	13/15/0
		C ₃ F ₈ 10–15%	89	60.6 ± 11.85	32/57		12	46/43/0

Table 1 (Continued)

Study	Country	Subject group	N	Age, year	Sex (F/M)	Tamponade, months	Follow-up, months	Phakia/pseudophakia/aphakia
Banerjee et al. (2017)	UK	Silicone Oil	49	45.5	3/49	3–5	24 (2–72)	38/14
		C ₃ F ₈ or SF ₆	15	45.5	3/13		24 (2–72)	11/5
Fang et al. (2017)	China	Silicone Oil	81	46.3 ± 13.3	19/31		12	
		Other	175	50.8 ± 16.6	81/125		12	
Lee et al. (2018)	South Korea	Silicone Oil 1300 cst	367	46.83 ± 15.00		3.36 ± 1.4		
		C ₃ F ₈	310	45.01 ± 20.11				
Cankurtaran et al. (2017)	Turkey	SiO 5000 cst or oxane 5700 cst	39	60.15 ± 10.84	7/32	3	33.95 ± 23.58	
		C ₃ F ₈ or scleral buckling	62	60.91 ± 9.79	43/29		32.62 ± 10.95	
Rodríguez et al. (2018)	USA	Silicone Oil	54	48.1 ± 16 (4–71)	18/62		10.3 ± 9	61/17/2
		Gas	23				10.3 ± 9	
Yasa et al. (2018)	Turkey	Silicone Oil 1000 cst	22	54 (13–79)	1/21	6.1	12 (12–20)	
		Silicone Oil 5000 cst	22	22 (4–68)	1/21	7.2	14 (12–24)	
Semeraro et al. (2019)	Italy	Silicone Oil	15	58.9 (12.8)	4/11	3.07 ± 0.2		6/9
		HSO	20	62.3 (16.7)	5/15	3.25 ± 0.4		13/7
Scheerlinck et al. (2018)	Netherlands	SiO 2000 cst	20	62 (30–74)	2/18	3.15	2	
		Gas	20	62 (45–75)	6/14		2	
Lyssek-Boron et al. (2019)	Poland	Silicone Oil 1000 cst	96	63.5 (15–86)		1–12	24	17/179
		SF ₆ or BSS	100					
Kakinoki et al. (2019)	USA	Silicone Oil	33	68 (43 a 87)	90/20			67/40/3
		Other	77					
Moharram et al. (2020)	Egypt	Silicone Oil	40	39.2 ± 12	12/28		6	32/4/4
		C ₃ F ₈ 15%	48	39.3 ± 9.5	28/20		6	36/11/1
Ratanapakorn et al. (2020)	Thailand	Silicone Oil 1000 or 1300 cst	50	52.96	19/32		12	34/12/4
		Silicone Oil 5000 or 5700 cS	50	54.26	17/31		12	33/15/2

BSS = balanced salt solution, C₃F₈ = octafluoropropane, cS = centistokes, F = female, HSO = heavy silicone oil, M = male, N = number of subjects included, SF₆ = sulphur hexafluoride.

were phakic, 968 were pseudophakic (36.22%) and 243 aphakic (9.09%); however, 18 studies did not provide this information (Hammer et al. 1997; Batman & Cekic 1999; Pertile & Claes 1999; Kapran et al. 2001; Tabandeh et al. 2000; Lu et al. 2002; Schmidt et al. 2003; Azad et al. 2003; Mete et al. 2011; Christensen & La Cour 2012; Do et al. 2014; Zafar et al. 2016; Fang et al. 2017; Lee et al. 2018; Yaşa & Alkin 2018; Scheerlinck et al. 2018; Cankurtaran et al. 2017; Murat n.d.).

Primary outcome: Adverse events associated with the use of SO compared to other vitreous tamponades

The included studies (Valone & McCarthy 1994; Davis et al. 1995; Hammer et al. 1997; Batman & Cekic 1999; Pertile & Claes 1999; Kapran et al. 2001; Tabandeh et al. 2000; Lu et al. 2002; Schmidt et al. 2003; Azad

et al. 2003; Tafoya et al. 2003 Ghosh et al. 2004; Scott et al. 2005; Soheil-ian et al. 2006; Yang et al. 2008; Boscia et al. 2008; Wong et al. 2009; Romano et al. 2010; Mete et al. 2011; Joussem et al. 2011; Teresio Avitabile et al. 2011; Nagpal et al. 2012; Christensen & La Cour 2012; Kocak & Koc 2013; Do et al. 2014; Oh et al. 2015; Caiado et al. 2015; Zafar et al. 2016; Scheerlinck et al. 2016; Lumi et al. 2016; Banerjee et al. 2017; Fang et al. 2017; Lee et al. 2018; Cankurtaran et al. 2017; Rodriguez et al. 2018; Yaşa & Alkin 2018; Semeraro et al. 2019; Scheerlinck et al. 2018; Lyssek-Boroń et al. 2019; Kakinoki et al. 2019; Moharram et al. 2020; Ratanapakorn et al. 2020; Murat n.d.) reported a total of 1024 adverse events associated with the use of SO. A detailed summary of clinical complications associated with the use of SO is shown in Table 2.

Intraocular pressure changes with vitreous endotamponade

The intraocular pressure (IOP) changes, either hypertension or hypotension, with the use of SO compared to other vitreous tamponades were analysed by 22 studies in the meta-analysis (Davis et al. 1995; Hammer et al. 1997; Batman & Cekic 1999; Pertile & Claes 1999; Scott et al. 2005; Soheil-ian et al. 2006; Boscia et al. 2008; Wong et al. 2009; Romano et al. 2010; Mete et al. 2011; Teresio Avitabile et al. 2011; Nagpal et al. 2012; Kocak & Koc 2013; Do et al. 2014; Zafar et al. 2016; Fang et al. 2017; Lee et al. 2018; Yaşa & Alkin 2018; Semeraro et al. 2019; Lyssek-Boroń et al. 2019; Moharram et al. 2020; Murat n.d.). A total of 332 patients (332 eyes) were enrolled in 17 studies (Hammer et al. 1997; Batman & Cekic 1999; Pertile & Claes 1999; Boscia et al. 2008; Wong et al. 2009; Romano et al. 2010; Mete et al. 2011; Teresio Avitabile et al. 2011; Nagpal et al. 2012;

Table 2. Clinical complications described in the studies included in the meta-analysis.

Study	Subject group	Vision				RRD	Macular Pucker	Corneal decompensation	Emulsification	Cataract
		OHT	loss	PVR	Hypotony					
Valone et al. (1994)	Silicone Oil 1000 cst							4		
	Silicone Oil 5000 cst							23		
Davis et al. (1995)	Silicone Oil 1000 cst	0			5	6		1	87	
	Silicone Oil 5000 cst	0			2	0		2	21	
Hammer et al. (1997)	Silicone Oil	2	8		1	12		2		
	SF ₆	1	8		0	12		0		
Batman et al. (1999)	Silicone Oil	1	12		2	2		3		
	C ₃ F ₈	0	12		4	3		1		
Pertile et al. (1999)	Silicone Oil	25								
	SF ₆	3								
Kapran et al. (2001)	Silicone Oil					11				
	C ₃ F ₈ or Other					6				
Tabandeh et al. (2000)	Silicone Oil		2							
	Gas		1							
Lu et al. (2002)	Silicone Oil					3	0		1	
	Gas					8	2		7	
Schmidt et al. (2003)	Silicone Oil					2				
	Other					27				
Azad et al. (2003)	Silicone Oil		3		2	3	2			
	Placebo		7		3	4	1			
Tafoya et al. (2003)	Silicone Oil 5000 cst							1	4	
	C ₃ F ₈ 14%	1							17	
Ghosh et al. (2004)	Silicone Oil			4		4			7	
	C ₃ F ₈ 16%			0		0			0	
Scott et al. (2005)	Silicone Oil 1000 cst	9	7		3	11		3	3	
	Silicone Oil 5000 cst	17	44		19	27		33	4	
Murat (n.d.)	Silicone Oil	4				8				
	HSO (Densiron)	3				2				
Soheilian et al. (2006)	Silicone Oil 1000 cst	2								
	Silicone Oil 5000 cst	6								
Yang et al. (2008)	Silicone Oil 5000 cst		2						13	
	C ₃ F ₈		1							
Boscia et al. (2008)	Silicone Oil 1300 cst	3					0	0	3	
	HSO	4					3	0	4	
Wong et al. (2009)	Silicone Oil	13						0		
	HSO	30						11		
Romano et al. (2010)	Silicone Oil	15						0		
	HSO	15						10		
Mete et al. (2011)	Silicone Oil 1000 cst	5				2			1	
	HSO	4				4			2	
Joussen et al. (2011)	Silicone Oil					8		0	2	
	HSO					6		0	3	
Avitabile et al. (2011)	Silicone Oil	2				5		2	9	
	HSO (Densiron)	4				2		6	4	
Nagpal et al. (2012)	Silicone Oil	7	1			4	4	2		
	Placebo	5	11			16	3	1		
Christensen et al. (2012)	Silicone Oil		9		1					
	C ₃ F ₈		7		0					
Kocak et al. (2013)	Silicone Oil 1000 cst	1	1	6		8	1	2	9	
	HSO (Densiron)	4	1	5		5	2	3	13	
Do et al. (2014)	Silicone Oil	1	33			3				
	SF ₆ or Placebo	0	41			36				
Oh et al. (2015)	Silicone Oil 1000 cst				1					
	Silicone Oil 5700 cst				0					
Caiado et al. (2015)	Silicone Oil					4				
	C ₃ F ₈ 15%					8				
Zafar et al. (2016)	Silicone Oil 1000 cst	11			1	6				
	Silicone Oil 5000 cst	9			1	2				
Scheerlinck et al. (2016)	Silicone Oil		20			4	0			
	Gas		21			1	1			
Lumi et al. (2016)	Silicone Oil 2000 cst					5			35	
	C ₃ F ₈ 10–15%					2				
Banerjee et al. (2017)	Silicone Oil		25						18	

Table 2 (Continued)

Study	Subject group	Vision				RRD	Macular Pucker	Corneal decompensation	Emulsification	Cataract
		OHT	loss	PVR	Hypotony					
Fang et al. (2017)	Gas		2						4	
	Silicone Oil	23								
	Other	27								
Lee et al. (2018)	Silicone Oil	5								
	C ₃ F ₈	1								
Cankurtaran et al. (2017)	Silicone oil					9				
	5000 cst or oxane 5700 cst									
	C ₃ F ₈ or scleral buckling					14				
Rodríguez et al. (2018)	Silicone Oil					4				
	Gas					7				
Yasa et al. (2018)	Silicone Oil 1000 cst	1		5	4		3	2	4	
	Silicone Oil 5000 cst	3		6	2		3	1	5	
Semeraro et al. (2019)	Silicone Oil	9				2		10		
	HSO	0				3		20		
Scheerlinck et al. (2018)	Silicone Oil 2000 cst		12							
	Gas		1							
Lyssek-Boron et al. (2019)	Silicone Oil 1000 cst	37								
	SF ₆ , or BSS	11								
Kakinoki et al. (2019)	Silicone Oil					9				
	Other					7				
Moharram et al. (2020)	Silicone Oil	4				2	9			
	C ₃ F ₈ 15%	5				0	10			
Ratanapakorn et al. (2020)	Silicone Oil		9			6		28		
	1000 cst or 1300 cst									
	Silicone Oil		7			5		18		
	5000 cst or 5700 cst									

BSS = balanced salt solution, C₃F₈ = octafluoropropane, cS = centistokes, F = female, HSO = heavy silicone oil, M = male, N = number of subjects included, OHT = ocular hypertension, PVR = proliferative vitreoretinopathy, RRD = retinal re-detachment, SF₆ = sulphur hexafluoride.

Kocak & Koc 2013; Do et al. 2014; Fang et al. 2017; Lee et al. 2018; Semeraro et al. 2019; Lyssek-Boroń et al. 2019; Moharram et al. 2020; Murat n.d.) that showed OHT with the use of SO (15%, *n* = 157/1048) vs other vitreous tamponades (including placebo) (10.87%, *n* = 116/1067). There was a significant difference in the risk of OHT (*p* = 0.0002, OR = 1.66; 95% CI = 1.27–2.18, *I*² = 66%) (Figure 2A) by using SO. Hypotony was analysed only in four studies (Hammer et al. 1997; Batman & Cekic 1999; Azad et al. 2003; Christensen & La Cour 2012). Although the results showed that only 2.76% (*n* = 6/217) of the eyes developed hypotony after filling with SO, the risk of hypotony was not significant lower in comparison with other tamponades (including placebo) (*p* = 0.48 OR = 0.67; 95% CI = 0.22–2.03, *I*² = 0%) (Figure 2B).

Unexplained visual loss after intraocular tamponades

A total of 12 studies provided data regarding the visual loss after the use of vitreous endotamponades at the final follow-up examination (Tabandeh

et al. 2000; Yang et al. 2008; Christensen & La Cour 2012; Nagpal et al. 2012; Kocak & Koc 2013; Scheerlinck et al. 2016, 2018; Banerjee et al. 2017). Data were provided in the form of number of patients whose visual acuity declined 2 Snellen lines. There was not significant difference in patients with SO vs other tamponades (including placebo) (*p* = 0.96, OR = 1.02; 95% CI = 0.42–2.49, *I*² = 78%) (Figure 2C). The risk of poor vision was comparable after the use of other tamponades (25%, *n* = 128/510) or SO (24.78%, *n* = 113/456).

Rate of retinal re-detachment

The rate of RRD after the use of intraocular endotamponades was analysed in 22 studies (Hammer et al. 1997; Batman & Cekic 1999; Kapran et al. 2001; Lu et al. 2002; Kakinoki et al. 2019; Schmidt et al. 2003; Azad et al. 2003; Ghosh et al. 2004; Mete et al. 2011; Moharram et al. 2020; Joussen et al. 2011; Teresio Avitabile et al. 2011; Nagpal et al. 2012; Kocak & Koc 2013; Do et al. 2014; Caiado et al. 2015; Scheerlinck et al. 2016;

Lumi et al. 2016; Cankurtaran et al. 2017; Rodriguez et al. 2018; Semeraro et al. 2019; Murat n.d.). The results showed a lower rate of RRD with the use of SO (14.6%, *n* = 118/807) than with other tamponades (including placebo) (17.81%, *n* = 178/999): There was a significant difference in patients with SO versus other endotamponades (including placebo) (*p* = 0.0009, OR = 0.65; 95% CI = 0.50–0.84, *I*² = 78%) (Figure 2D).

Anterior segment complications

Anterior segment complications, mainly corneal abnormalities, including corneal oedema, opacity or band keratopathy, were reported in five studies (Hammer et al. 1997; Batman & Cekic 1999; Teresio Avitabile et al. 2011; Nagpal et al. 2012; Yaşa & Alkın 2018). The results showed that 8.27% of the eyes filled with SO (*n* = 12/145) reported corneal decompensation. There was no significant difference after undergoing PPV with SO and other endotamponades (*p* = 0.89, OR = 1.08; 95% CI = 0.38–3.05, *I*² = 14%) (Figure 2E).




Fig. 2. Meta-analysis of the clinical complications associated to the use of silicone oil (SO) as a vitreous substitute. (A) Risk of ocular hypertension associated to the use of SO. Test for overall effect: $Z = 3.68$ ($p = 0.0002$). Test for heterogeneity: $\chi^2 = 47.53$ ($p < 0.001$), $I^2 = 66\%$. (B) Risk of ocular hypotony associated to the use of SO. Test for overall effect: $Z = 0.72$ ($p = 0.47$). Test for heterogeneity: $\chi^2 = 1.16$ ($p = 0.76$), $I^2 = 0\%$. (C) Risk of loss of vision associated to the use of SO. Test for overall effect: $Z = 0.04$ ($p = 0.96$). Test for heterogeneity: $\chi^2 = 49.41$ ($p < 0.001$), $I^2 = 78\%$. (D) Risk of retinal re-detachment associated to the use of SO. Test for overall effect: $Z = 3.33$ ($p < 0.001$). Test for heterogeneity: $\chi^2 = 95.21$ ($p < 0.001$), $I^2 = 78\%$. (E) Risk of corneal decompensation associated to the use of SO. Test for overall effect: $Z = 0.14$ ($p = 0.89$). Test for heterogeneity: $\chi^2 = 4.65$ ($p = 0.33$), $I^2 = 14\%$. (F) Risk of cataract associated to the use of SO. Test for overall effect: $Z = 1.22$ ($p = 0.22$). Test for heterogeneity: $\chi^2 = 3.15$ ($p = 0.53$), $I^2 = 0\%$. (G) Risk of macular pucker associated to the use of SO. Test for overall effect: $Z = 0.06$ ($p = 0.95$). Test for heterogeneity: $\chi^2 = 3.05$ ($p = 0.80$), $I^2 = 0\%$. (H) Risk of proliferative vitreoretinopathy associated to the use of SO. Test for overall effect: $Z = 0.01$ ($p = 0.99$). Test for heterogeneity: $\chi^2 = 0.40$ ($p = 0.94$), $I^2 = 0\%$. (I) Risk of emulsification associated to the use of SO. Test for overall effect: $Z = 1.36$ ($p = 0.17$). Test for heterogeneity: $\chi^2 = 17.65$ ($p = 0.001$), $I^2 = 77\%$.

Cataracts

The rate of cataract progression was clearly reported in five studies (Tafaya et al. 2003; Ghosh et al. 2004; Teresio Avitabile et al. 2011; Kocak & Koc 2013; Banerjee et al. 2017). Visually significant cataract was noted in the 45% of SO eyes (40/88) and in the 70% of the eyes filled with other endotamponades (28/40). The mean of SO tamponade duration and follow-up time in the involved studies was, respectively, 4.33 months (range: 2–10) and 15.26 months (range: 2 months to 7 years). There was no significant difference in cataract complication between patients with SO and the other

group ($p = 0.57$, $OR = 0.76$; 95% $CI = 0.76–1.98$, $I^2 = 0\%$) (Figure 2F).

Regarding SO 1000 cst and SO 5000 cst, it was not possible to carry out the statistical analysis since there were only two studies with enough data (Davis et al. 1995; Zafar et al. 2016).

Posterior segment complications

Retinal complications such as macular pucker or PVR were reported in seven (Lu et al. 2002; Azad et al. 2003; Boscia et al. 2008; Nagpal et al. 2012; Kocak & Koc 2013; Scheerlinck et al. 2016; Moharram et al. 2020) and three (Ghosh et al. 2004; Kocak & Koc 2013; Yaşa & Alkin 2018)

studies, respectively. Macular pucker was observed in the 6.7% of cases with SO affecting 16 of 238 eyes and PVR in 18.7% ($n = 15/80$) of the eyes filled with SO. However, the results were no significant ($p = 0.80$, $OR = 0.95$; 95% $CI = 0.48–1.87$, $I^2 = 0\%$) and ($p = 0.99$, $OR = 0.98$; 95% $CI = 0.39–2.44$, $I^2 = 0\%$) (Figures 2G and H).

Emulsification

Emulsification between conventional SO and heavy SO was analysed in nine reports (Boscia et al. 2008; Wong et al. 2009; Romano et al. 2010; Metz et al. 2011; Joussen et al. 2011; Teresio

Table 3. Summary of the meta-analysis of the clinical complications associated with the use of silicone oil as a vitreous substitute including only clinical trials.

Comparison	N	OR	95% CI	p (random effects model)	I ² (%)	p (heterogeneity)
Risk of ocular hypertension associated with the use of SO	9	1.27	0.56–2.90	0.57	52	0.04
Risk of loss of vision associated with the use of SO	5	0.76	0.46–1.26	0.29	64	0.02
Risk of retinal re-detachment associated with the use of SO	8	0.38	0.25–0.59	<0.001	78	<0.001
Risk of ocular hypotony associated with the use of SO	3	0.61	0.18–2.12	0.44	0	0.58
Risk of macular pucker associated with the use of SO	3	0.68	0.18–2.62	0.58	12	0.32
Risk of corneal decompensation associated with the use of SO	4	1.23	0.28–5.29	0.78	35	0.25

CI = confidence interval, N = number of studies included, OR = odds ratio, SO = silicone oil.

Avitabile et al. 2011; Kocak & Koc 2013; Semeraro et al. 2019; Murat n.d.); however, four articles did not provide enough data and were not included in the comparisons. Nine (9.45%) per cent of eyes filled with conventional SO showed emulsification, but there was no significant difference ($p = 0.17$, OR = 4.50; 95% CI = 0.52–39.02 $I^2 = 77\%$) compared to heavy SO (Figure 2I).

After sensitivity analysis, the exclusion of individual studies did not alter the significant results in the study for OH. However, meta-analysis after the exclusion of the by Scheerlinck et al. (2016) yielded no significant differences in the comparison for loss of vision. In addition, the exclusion of the study by Schmidt et al. (2003) or Do et al. (2014) showed no significant differences for the analysis of RRD. However, the I^2 analysis in the majority of the comparisons showed moderate heterogeneity in the pooled studies, indicating the effect of different tamponades in control groups.

In an attempt to reduce the heterogeneity, we also performed a subgroup analysis, using only the patients enrolled in RCTs. In Table 3 is summarized the meta-analysis of the adverse events after the use of SO including only the patients enrolled in RCTs. The use of SO was associated with a significant lower risk of RRD compared to other endotamponades (including placebo) ($p < 0.0001$, OR = 0.38; 95% CI = 0.25–0.59, $I^2 = 78\%$). There were no significant differences in the analysis of other complications. After sensitivity analysis, the exclusion of the study by Do et al. (2014) yielded no significant differences, but the I^2 value showed higher heterogeneity. The effect of different surgical histories might have also contributed to increasing the heterogeneity.

Secondary outcome: Adverse events and rate of emulsification associated with the use of low and high SO viscosity

Intraocular pressure (IOP) changes including OH and hypotony were analysed by eight studies (Valone & McCarthy 1994; Davis et al. 1995; Scott et al. 2005; Soheilian et al. 2006; Oh et al. 2015; Zafar et al. 2016; Yaşa & Alkin 2018; Ratanapakorn et al. 2020) that showed no significant differences with the use of low and high SO viscosity. ($p = 0.10$, OR = 1.67; 95% CI = 0.91–3.08, $I^2 = 23\%$) and ($p = 0.68$, OR = 0.84; 95% CI = 0.38–1.89, $I^2 = 0\%$) (Table 4). The risk of RRD between different SO viscosities was assessed by four studies (Davis et al. 1995; Scott et al. 2005; Zafar et al. 2016; Ratanapakorn et al. 2020). We found no significant differences between low and high SO viscosity (OR, 0.68; 95% CI, 0.38–1.22, $I^2 = 0$) (Table 4), and we found no significant differences between low and high SO viscosity ($p = 0.19$, OR = 0.68; 95% CI = 0.38–1.22, $I^2 = 23$) (Table 4). Five studies reported the emulsification of low and high SO viscosity (Davis et al. 1995; Scott et al. 2005; Soheilian et al. 2006; Zafar et al. 2016; Yaşa & Alkin 2018); our results did not show significant differences ($p = 0.56$, OR = 1.19, 95% CI = 0.67–2.11, $I^2 = 0\%$) (Table 4). There was not enough information about the rest of the outcomes; thus, a comparison of the tamponade effects on the risk of vision loss, PVR and macular pucker formation was not possible. The I^2 value in this subgroup analysis showed low heterogeneity in the pooled studies.

Discussion

In this analysis, we examined the adverse events in 4,717 patients who underwent SO and other vitreous tamponades, including placebo in

performing PPV, have been examined. Forty-two studies indexed in databases were identified for inclusion in this analysis (Valone & McCarthy 1994; Davis et al. 1995; Hammer et al. 1997; Batman & Cekic 1999; Pertile & Claes 1999; Z. Kapran et al. 2001; Tabandeh et al. 2000; Lu et al. 2002; Schmidt et al. 2003; Azad et al. 2003; Ghosh et al. 2004; Scott et al. 2005; Soheilian et al. 2006; Yang et al. 2008; Boscia et al. 2008; Wong et al. 2009; Romano et al. 2010; Mete et al. 2011; Jousen et al. 2011; Teresio Avitabile et al. 2011; Nagpal et al. 2012; Christensen & La Cour 2012; Kocak & Koc 2013; Do et al. 2014; Oh et al. 2015; Caiado et al. 2015; Zafar et al. 2016; Scheerlinck et al. 2016; Lumi et al. 2016; Fang et al. 2017; Lee et al. 2018; Cankurtaran et al. 2017; Rodriguez et al. 2018; Yaşa & Alkin 2018; Semeraro et al. 2019; Scheerlinck et al. 2018; Lyssek-Boroń et al. 2019; Kakinoki et al. 2019; Moharram et al. 2020; Ratanapakorn et al. 2020; Banerjee et al. 2017; Murat n.d.). Despite that there is a likelihood of inputting moderate heterogeneity when non-RCT studies are entered in the comparisons, we believe that all the included studies represent a piece of adequate and valuable information regarding SO and other tamponade agents in retinal surgery and a broad comparison might be possible. Eight articles reporting on eight RCTs (Hammer et al. 1997; Batman & Cekic 1999; Do et al. 2014; Azad et al. 2003; Nagpal et al. 2012; Boscia et al. 2008; Jousen et al. 2011; Teresio Avitabile et al. 2011) were included in the analysis. However, our data were collected from studies published after 1994, when the FDA approved the use of SO as a vitreous substitute. All included studies made comparisons between SO and other

Table 4. Summary of the meta-analysis of the clinical complications associated with the use of high or low viscosity silicone oil as a vitreous substitute.

Comparison	N	OR	95% CI	p (random effects model)	I ² (%)	p (heterogeneity)
Risk of ocular hypertension associated with the use of HSO	5	1.19	0.67–2.11	0.56	0	0.60
Risk of ocular hypotony associated with the use of HSO	5	0.84	0.38–1.89	0.68	0	0.70
Risk of retinal re-detachment associated with the use of HSO	4	0.68	0.38–1.22	0.19	0	0.59
Risk of emulsification associated with the use of HSO	5	1.67	0.91–3.08	0.10	23	0.27

CI = confidence interval, HSO = high silicone oil, N = number of studies included, OR = odds ratio, SO = silicone oil.

tamponades, such as gases (SF₆, C₂F₆, C₃F₈), heavy SO or placebo. In addition, for our secondary outcome, 1055 patients from eight studies were analysed to compare complication rates regarding oil viscosity used (1000–2000 cst versus 5000 cst SO viscosity).

Those patients with SO tamponade were followed for at least 3 months with the SO in situ, and long-term outcomes of both groups were observed and compared. Although long-term complications of SO tamponade after PPV (Morphis et al. 2012; Feng et al. 2017; Abu-Yaghi et al. 2020) have been known for quite time, SO remains one of the favourites agents for long-standing vitreous replacement (Saleh et al. 2020). However, when discussing the safety of SO as endotamponade, the risk of complications cannot be neglected. A total of 921 adverse events associated with the use of SO were reported in our analysis. Most surgeons advocate ROSO after 3–6 months due to the increased rate of complications with persistent tamponades. The mean duration time before the ROSO in the included studies (Soheilian et al. 2006; Boscia et al. 2008; Romano et al. 2010; Mete et al. 2011; Christensen & La Cour 2012; Nagpal et al. 2012; Do et al. 2014; Oh et al. 2015; Scheerlinck et al. 2016, 2018; Zafar et al. 2016; Banerjee et al. 2017; Cankurtaran et al. 2017; Lee et al. 2018; Yaşa & Alkın 2018; Lyssek-Boroń et al. 2019; Semeraro et al. 2019) was 4.35 ± 3 months in our review.

The true incidence of HTO after SO injection is difficult to ascertain because the baseline and intraoperative characteristics are diverse among patients included in the different analysis. The reported incidence of raised IOP varies from 3% to 40% in patients receiving conventional SO tamponade (Morphis et al. 2012; Dooley et al. 2016) and from 14% to 30.7% in patients with Heavy SO (Tognetto et al. 2005; Wolf et al. 2003; David Wong et al. 2005). In

this study, the risk of raised IOP after surgery in the SO group and in the other tamponades was 15% and 10.87%, respectively. We found that SO has a statistically significant greater effect on raising IOP than other agents. This outcome was different from that reported by a recent meta-analysis by Feng et al. (2017). We supposed that the differences might be attributable to a small sample size that may have limited its result since the subgroup analysis of RCTs also failed to demonstrate significance in raised IOP in this review.

It has been hypothesized that SO long-term increased IOP depends on an open-angle mechanism and the presence of SO in the anterior chamber may contribute significantly to IOP increase, blocking the outflow pathway through the trabecular meshwork (Nguyen et al. 1992; Honavar et al. 1999; Romano et al. 2010). Although it has been reported that low-viscosity SO may trigger a greater emulsification tendency compared to high-viscosity SO (Crisp et al. 1987; Heidenkummer et al. 1991; Zafar et al. 2016; Ratanapakorn et al. 2020; Nakamura et al. n.d.), especially when the oil is intended to serve as a prolonged tamponade, the current clinical evidence in the literature from RCTs is limited and scarce. This analysis did not show differences in the rate of emulsification regardless of oil viscosity used. It is obvious that the higher the viscosity, the lower the dispersion capacity, but the existence of emulsification requires the presence of surfactant agents that do not always depend on the SO used (Nazir et al. 2012). This lack of correlation between emulsification and viscosity is not new and it was supported by recent studies (Scott et al. 2005; Abu-Yaghi et al. 2020; Ratanapakorn et al. 2020). However, findings of eyes with SO emulsification without IOP elevation (Nguyen et al. 1992; Barr et al. 1993; Gonvers 1996; Honavar et al. 1999)

may suggest different etiological mechanisms and warrant further studies to resolve this controversy. There were not enough data to examine the effect of duration of SO as tamponade among different SO viscosities and the effect of different underlying diseases.

Ocular hypotony is a noted complication in the use of SO for the tamponade of complicated RD with PVR (Leaver et al. 1979; Jonas et al. 2001a; Song et al. 2010; Issa et al. 2020; Kim et al. 2010). In addition, after ROSO, the incidence of hypotony ranges from 2% to 40% of cases (Casswell & Gregor 1987a, 1987b; BASSAT et al. 2000; Kim et al. 2010; Moisseiev et al. 2013; Al-Wadani et al. 2014a; Zafar et al. 2016; Issa et al. 2020). Our analysis concluded that although there was a difference between the hypotony in both groups, 2.76% of eyes filled with SO, it was not statistically significant. This trend was supported by previous studies (Barr et al. 1993; Feng et al. 2017). We believe that their retrospective nature and the relatively small number of cases included may have limited this result. In addition, there were no data about the average IOP preoil removal surgery, the onset of hypotony after ROSO and whether reinsertion of oil for hypotony management was required.

The subgroup analysis between low and high SO viscosity also failed to show differences (3.25% and 5.97% of patients reported hypotony, respectively). This result was in the same line as recent studies (Scott et al. 2005; Abu-Yaghi et al. 2020; Ratanapakorn et al. 2020).

Although cataract development is one of the commonest causes of visual loss after vitrectomy, its pathogenesis is still unclear, and several hypotheses have been formulated without any conclusions. This complication can be corrected with further surgical procedure (Do et al. 2014; Post-Vitrectomy Cataract Acceleration in Phakic Eyes:

A Review - Khusbu Keyal - Discovery Medicine n.d.), but phacoemulsification with intraocular lens implantation in vitrectomized eyes could be challenging and may have a high risk of complications (Do et al. 2014; Fenberg et al. 2016). In this sense, many surgeons decide to perform phacovitrectomy in a single procedure. Despite that it has some advantages, a higher chance of anterior segment inflammation must be taken into consideration, especially when it is performed in eyes with diabetic tractional retinal detachment (Yorgun et al. 2016; Tayyab et al. 2017).

Prolonged direct contact of SO with the posterior part of the lens could be an important cause accelerating the development of cataracts after PPV compared to other endotamponades (Titiyal et al. 2017; Schwartz et al. 2020). However, we found cataract progression in 42.70% of the eyes filled with SO, slightly lower than literature reported, which varies widely from 55% to 80% (Scholda et al. 1997; Tafuya et al. 2003; Badrinath et al. 2004; Shah et al. 2008; Li et al. 2010; Ozdek et al. 2011; Antoun et al. 2016; Brănișteanu et al. 2017; Issa et al. 2020). This result could be explained by the heterogeneity in the pooled studies, the lack of cataract data collection in comparative studies between SO and other endotamponades and the variability in the residence time of SO tamponade before ROSO.

Although lower mean interval time between PPV and cataract surgery has been reported in eyes filled with SO (Abu-Yaghi et al. 2020), there were not enough data in the included studies to verify it, so it could be interesting to carry out future studies being rigorous in data collection.

Since SO leads to long-term complications and the rate of RRD is not influenced by the duration of intraocular SO (Falkner et al. 2001; Issa et al. 2020), the ROSO from the eye is recommended as early as possible to avoid the initiation or worsening of oil associated complications.

The recurrence rate of RRD after ROSO in the literature varies widely from 0% to 35.5% (McCuen et al. 1985; Casswell & Gregor 1987a, 1987b; Federman & Schubert 1988; Lean et al. 1992; Hutton et al. 1994; Pavlovic S et al. 1995; Scholda et al. 1997; Scott et al. 1999; BASSAT et al. 2000;

Scholda et al. 2000; Jonas et al. 2001b; Sharma et al. 2002; Wolf et al. 2003; David Wong et al. 2005; Tognetto et al. 2005; Ziya Kapran & Acar 2007; Avitabile et al. 2008; Lam et al. 2008; Falkner-Radler et al. 2011; Morphis et al. 2012; Moisseiev et al. 2013; Al-Wadani et al. 2014b; Ghoraba et al. 2014; Tavares et al. 2015; Dooley et al. 2016; Zafar et al. 2016; Dhalla et al. 2017; Li et al. 2020) with majority of studies reporting values in the 8%–12% range (Issa et al. 2020). The risk factors of retinal re-detachment after ROSO include the presence of PVR, new retinal breaks, the absence of an encircling band or no relaxing retinotomy performed during the primary procedure, the number of previous unsuccessful RD surgeries or the incomplete removal of the vitreous base or posterior hyaloid membrane (Goezinne et al. 2007; Moisseiev et al. 2013; Al-Wadani et al. 2014b).

We found that retinal re-detachment occurred in 14.6% of eyes filled with conventional SO and in 17.81% in the other agents. The risk of RRD was statistically significant lower in the SO group than in the other tamponades. This result was different from that reported by recent meta-analysis by Feng et al. (2017) and Schwartz et al. (2014). We supposed that the difference might be attributable to a larger number of studies (22 studies) included in the analysis and the underlying causes for RD. Furthermore, the subgroup analysis, using only RCTs, also noted that eyes filled with other tamponade agents may need more operations. This not being the case in the analysis between low and high SO viscosity did not show differences as in other previous studies (Scott et al. 2005; Abu-Yaghi et al. 2020; Ratanapakorn et al. 2020).

The advances in PPV instrumentation in the last decade, the use of wide-field viewing systems, which allow an aggressive removal of the vitreous base, and better identification of iatrogenic breaks, in combination with the application of different surgical techniques, might have a notorious impact on the low re-detachment rate in present days when compare with series made 20 years ago (Jonas et al. 2001b). However, there were no enough data to assess the effect of prophylactic surgical manoeuvres such as 360° retinopexy, the use of perfluorocarbon

liquids, internal limiting membrane peeling, or encircling buckles on the rate of RRD at the time of ROSO surgery. Thus, more RCTs comparing anatomical and functional outcomes after different ROSO strategies need to be conducted to guide surgeon's selection of surgical technique.

SO-related visual loss (>2 Snellen lines) during SO tamponade or at the time of ROSO is one of the recent issues that have provoked rising concern and led surgeons to reconsider the use of SO as tamponade. Although its prevalence and the exact aetiology remain still unclear, there is a rising number of series reporting central visual loss without any apparent explanation in uncomplicated surgeries with SO as tamponade (La Cour et al. 2010; Moya et al. 2015; Scheerlinck et al. 2016; Chen et al. 2020). It has also been reported in cases of macular sparing RD, up to 50%, where patients had seemingly a good VA potential (Moya et al. 2015). However, the underlying mechanisms need further investigations as poor visual acuity has also been documented with other tamponades and successful macula-on RD surgery (Lai et al. 2011; Mitry et al. 2011; Li 2003; Okamoto et al. 2013; Di Lauro et al. 2015).

We found no significant difference in patients with SO and with others, but approximately 25% of cases can lose vision after PPV with any vitreous tamponade agent.

In addition, the subgroup analysis between low and high SO viscosity and RCTs did not show differences as well. Similar results have been reported in previous studies (Scott et al. 2005; Feng et al. 2017; Abu-Yaghi et al. ; Ratanapakorn et al. 2020). Therefore, further studies are needed to evaluate the risk of SO-related visual loss and other explanations in macula on RD such as the effect of released factors produced by retinal ischemia on the macula area or the ability to dissolve lipids from membrane cells (Pastor Jimeno et al. 2007) need to be considered. Finally, as in other reviews (Cox et al. 1995; Feng et al. 2017) other complications such as corneal abnormalities, ERM, or PVR did not show significant differences between SO and other agents. Thus, it is not clear whether the risk of these common complications is higher with SO than with other tamponades. Clarifying this issue requires further prospective studies.

Limitations and strengths

It is necessary to emphasize the limitations of this meta-analysis. First, the retrospective nature of some studies with many confounding variables might increase the risk of bias. Second, the heterogeneity in some cases was moderate in the pooled studies that prevent firm conclusions in the comparisons and might also increase the risk of bias. Third, the number of studies and the quantity of data about some endpoints were insufficient and inconsistent between studies, increasing again the risk of bias. Fourth, English language bias may be present in this meta-analysis as only studies reported in English have been included; however, its significance in meta-analysis research is unclear at present (Egger et al. 1997). Finally, the time of follow-up, baseline features, surgical strategies and type of endotamponade agent are not standardized between studies making challenging the assessment based on unified endpoints. In addition to the limitations described above, it must be taken into account that the quality of the different SO used is not the same and that can determine the results. As an example, emulsification can be influenced by different brands based on the different degrees of purification. There are multiple factors of the patient himself that can favour it, but also the concentration of low molecular weight components (LWMC) and polydispersity (Nakamura et al. 1991; Pastor et al. 1998), and this may have an obvious influence on some of the results of clinical studies (Dresp, 2021).

Despite the majority of the results of this review are supported by previous studies in the literature, we express reservations regarding some conclusions, especially in membrane formation or rate of emulsification. Nevertheless, this review has also several strengths. We believe that it is the largest comparison made regarding SO and other vitreous tamponade agents, faithfully representing real clinical data. We have applied strict criteria in the identification and assessment of included studies. Also, we have provided different subgroup analyses strategies (RCTs and low and high SO viscosity) and sensitivity analysis to minimize the heterogeneity. Even with these limitations, this review counted with enough and updated data to

examine broadly the differences between SO and other vitreous tamponades, including placebo. Also, it contributes significantly to a better understanding of risk complications with the use of different endotamponade agents in performing PPV.

Conclusions

Among the available studies, we can conclude that the risk of raised IOP is higher with SO in different surgical histories and this result should be more of a consideration when selecting SO as an endotamponade in patients with a history of glaucoma. It also demonstrates that SO has favourable outcomes in terms of lower risk of retinal re-detachment. In the risk of bad outcomes that can cause severe visual impairment, we did not find any differences. However, it is still unclear when the SO is required and how to use it efficiently to minimize the related complications. Prospective RCTs with large sample sizes are required to clarify current controversies between different tamponade agents.

References

- Abu-Yaghi NE, Abu Gharbieh YA, Al-Amer AM et al. (2020): Characteristics, fates and complications of long-term silicone oil tamponade after pars plana vitrectomy. *BMC Ophthalmol* **20**: 1–7. <https://doi.org/10.1186/s12886-020-01608-5>.
- Alovisi C, Panico C, De Sanctis U & Eandi CM (2017): Vitreous substitutes: old and new materials in vitreoretinal surgery. *J Ophthalmol Hindawi Limited*. **2017**: 1–6. <https://doi.org/10.1155/2017/3172138>.
- Al-Wadani SF, Abouammoh MA & Abu El-Asrar AM (2014a): Visual and anatomical outcomes after silicone oil removal in patients with complex retinal detachment. *Int Ophthalmol* **34**: 549–556.
- Al-Wadani SF, Abouammoh MA & Abu El-Asrar AM (2014b): Visual and anatomical outcomes after silicone oil removal in patients with complex retinal detachment. *Int Ophthalmol* **34**: 549–556. <https://doi.org/10.1007/s10792-013-9857-9>.
- Antoun J, Azar G, Jabbour E, Kourie HR, Slim E, Schakal A & Jalkh A (2016): Vitreoretinal surgery with silicone oil tamponade in primary uncomplicated rhegmatogenous retinal detachment. *Retina* **36**: 1906–1912. <https://doi.org/10.1097/IAE.0000000000001008>.
- Avitabile T, Bonfiglio V, Buccoliero D, Castiglione F, Reibaldi M, Castaing M & Mistretta A (2011): Heavy versus standard silicone oil in the management of retinal detachment with macular holes in myopic eyes. *Retina* **31**: 540–546. <https://doi.org/10.1097/IAE.0b013e3181ec80c7>.
- Avitabile T, Longo A, Lentini G & Reibaldi A (2008): Retinal detachment after silicone oil removal is prevented by 360° laser treatment. *Br J Ophthalmol* **92**: 1479–1482. <https://doi.org/10.1136/bjo.2008.140087>.
- Azad R, Ravi K, Talwar D & Kumar RN (2003): Pars plana vitrectomy with or without silicone oil endotamponade in post-traumatic endophthalmitis. *Graefes Arch Clin Exp Ophthalmol* **241**: 478–483. <https://doi.org/10.1007/s00417-003-0670-4>.
- Badrinath SS, Gopal L, Sharma T et al. (2004): Use of silicone oil in the management of complex retinal detachment – an indian experience. *Int Ophthalmol* **25**: 129–142. <https://doi.org/10.1007/s10792-003-7609-y>.
- Banerjee PJ, Chandra A, Petrou P & Charteris DG (2017): Silicone oil versus gas tamponade for giant retinal tear-associated fovea-sparing retinal detachment: a comparison of outcome. *Eye (Basingstoke)* **31**: 1302–1307. <https://doi.org/10.1038/eye.2017.167>.
- Barr CC, Lai MY, Lean JS, Linton KLP, Trese M, Abrams G, Ryan SJ & Azen SP (1993): Postoperative intraocular pressure abnormalities in the silicone study: silicone study report 4. *Ophthalmology* **100**: 1629–1635. [https://doi.org/10.1016/S0161-6420\(93\)31425-9](https://doi.org/10.1016/S0161-6420(93)31425-9).
- Bassat IB, Desatnik H, Alhalel A, Treister G & Moisseiev J (2000): Reduced rate of retinal detachment following silicone oil removal. *Retina* **20**: 597. <https://doi.org/10.1097/00006982-200011000-00002>.
- Batman C & Cekic O (1999): Vitrectomy with silicone oil or long-acting gas in eyes with giant retinal tears: long-term follow-up of a randomized clinical trial. *Retina* **19**: 188–192. <https://doi.org/10.1097/00006982-199903000-00002>.
- Boscia F, Furino C, Recchimurzo N, Besozzi G, Sborgia G & Sborgia C (2008): Oxane HD vs silicone oil and scleral buckle in retinal detachment with proliferative vitreoretinopathy and inferior retinal breaks. *Graefes Arch Clin Exp Ophthalmol* **246**: 943–948. <https://doi.org/10.1007/s00417-008-0806-7>.
- Brănișteanu DC, Moraru A & Bilha A (2017): Anatomical results and complications after silicone oil removal. *Romanian J Ophthalmol* **61**: 261–266. <https://doi.org/10.22336/rjo.2017.47>.
- Caiado RR, Magalhães O, Badaró E et al. (2015): Effect of lens status in the surgical success of 23-gauge primary vitrectomy for the management of rhegmatogenous retinal detachment: the pan american collaborative retina study (PACORES) group results. *Retina* **35**: 326–333. <https://doi.org/10.1097/IAE.0000000000000307>.
- Cankurtaran V, Citirik M, Simsek M, Tekin K & Teke MY (2017): Anatomical and functional outcomes of scleral buckling versus primary vitrectomy in pseudophakic retinal

- detachment. *Bosnian J Basic Med Sci* **17**: 74–80. <https://doi.org/10.17305/bjbm.2017.1560>.
- Casswell AG & Gregor ZJ (1987a): Silicone oil removal. I. The effect on the complications of silicone oil. *Br J Ophthalmol* **71**: 893–897. <https://doi.org/10.1136/bjo.71.12.893>.
- Casswell AG & Gregor ZJ (1987b): Silicone oil removal. II. Operative and postoperative complications. *Br J Ophthalmol* **71**: 898–902. <https://doi.org/10.1136/bjo.71.12.898>.
- Chen Y, Kearns VR, Zhou L, Sandinha T, Lam WC, Steel DH & Chan YK (2020): Silicone oil in vitreoretinal surgery: indications, complications, new developments and alternative long-term tamponade agents. *Acta Ophthalmol* **99**: 240–250. <https://doi.org/10.1111/aos.14604>.
- Christensen UC & La Cour M (2012): Visual loss after use of intraocular silicone oil associated with thinning of inner retinal layers. *Acta Ophthalmol* **90**: 733–737. <https://doi.org/10.1111/j.1755-3768.2011.02248.x>.
- Cibis PA, Becker B, Okun E & Canaan S (1962): The use of liquid silicone in retinal detachment surgery. *Arch Ophthalmol* **68**: 590–599. <https://doi.org/10.1001/archoph.1962.00960030594005>.
- “Cochrane Handbook for Systematic Reviews of Interventions | Cochrane Training.” (n.d.) Accessed January 5, 2021. <https://training.cochrane.org/cochrane-handbook-systematic-reviews-interventions>.
- Cox MS, Azen SP, Barr CC, Linton KLP, Diddie KR, Lai MY, Freeman HM & Irvine A (1995): Macular pucker after successful surgery for proliferative vitreoretinopathy: silicone study report 8. *Ophthalmology* **102**: 1884–1891. [https://doi.org/10.1016/S0161-6420\(95\)30779-8](https://doi.org/10.1016/S0161-6420(95)30779-8).
- Crisp A, de Juan E & Tiedeman J (1987): Effect of silicone oil viscosity on emulsification. *Arch Ophthalmol* **105**: 546–550. <https://doi.org/10.1001/archoph.1987.01060040116047>.
- Davis JL, Serfass MS, Lai MY, Trask DK & Azen SP (1995): Silicone oil in repair of retinal detachments caused by necrotizing retinitis in HIV infection. *Arch Ophthalmol* **113**: 1401–1409. <https://doi.org/10.1001/archoph.1995.01100110061026>.
- DerSimonian R & Laird N (1986): Meta-analysis in clinical trials. *Control Clin Trials* **7**: 177–188. [https://doi.org/10.1016/0197-2456\(86\)90046-2](https://doi.org/10.1016/0197-2456(86)90046-2).
- Dhalla K, Kapasa I & Odouard C (2017): Incidence and risk factors associated with retinal redetachment after silicone oil removal in the African population. *Int Ophthalmol* **37**: 583–589. <https://doi.org/10.1007/s10792-016-0309-1>.
- Di Lauro S, Castrejón M, Fernández I, Rojas J, Coco RM, Sanabria MR, Rua ERDL & Carlos Pastor J (2015): Loss of visual acuity after successful surgery for macula-on rhegmatogenous retinal detachment in a prospective multicentre study. *J Ophthalmol* **2015**: 1–8. <https://doi.org/10.1155/2015/821864>.
- Do T, Hon DN, Aung T, Hien NDTN & Cowan CL (2014): Bacterial endogenous endophthalmitis in vietnam: a randomized controlled trial comparing vitrectomy with silicone oil versus vitrectomy alone. *Clin Ophthalmol* **8**: 1633–1640. <https://doi.org/10.2147/OPTH.S67589>.
- Dooley IJ, Duignan ES & Kilmartin DJ (2016): Long-term heavy silicone oil intraocular tamponade. *Int Ophthalmol* **36**: 3–7. <https://doi.org/10.1007/s10792-015-0068-4>.
- Dresp JH (2021): Benchmarking different brands of silicone oils. *Graefes Arch Clin Exp Ophthalmol* **259**: 13–20. <https://doi.org/10.1007/s00417-020-04809-2>.
- Egger M, Zellweger-Zähner T, Schneider M, Junker C, Lengeler C & Antes G (1997): Language bias in randomised controlled trials published in English and German. *Lancet* **350**: 326–329. [https://doi.org/10.1016/S0140-6736\(97\)02419-7](https://doi.org/10.1016/S0140-6736(97)02419-7).
- Falkner CI, Binder S & Kruger A (2001): Outcome after silicone oil removal. *Br J Ophthalmol* **85**: 1324–1327. <https://doi.org/10.1136/bjo.85.11.1324>.
- Falkner-Radler CI, Smretschign E, Graf A & Binder S (2011): Outcome after silicone oil removal and simultaneous 360° endolaser treatment. *Acta Ophthalmol* **89**: e46–e51. <https://doi.org/10.1111/j.1755-3768.2010.02059.x>.
- Fang Y, Long Q, Wang X, Jiang R & Sun X (2017): Intraocular pressure 1 year after vitrectomy in eyes without a history of glaucoma or ocular hypertension. *Clin Ophthalmol* **11**: 2091–2097. <https://doi.org/10.2147/OPTH.S144985>.
- Federman JL & Schubert HD (1988): Complications associated with the use of silicone oil in 150 eyes after retina-vitreous surgery. *Ophthalmology* **95**: 870–876. [https://doi.org/10.1016/S0161-6420\(88\)33080-0](https://doi.org/10.1016/S0161-6420(88)33080-0).
- Fenberg MJ, Hainsworth KJ, Rieger FG & Hainsworth DP (2016): Vitrectomy as a risk factor for complicated cataract surgery. *Missouri Med* **113**: 44–47. <https://pubmed.ncbi.nlm.nih.gov/27113974/>.
- Feng X, Li C, Zheng Q et al. (2017): Risk of silicone oil as vitreous tamponade in pars plana vitrectomy: a systematic review and meta-analysis. *Retina* **37**: 1989–2000. <https://doi.org/10.1097/IAE.0000000000001553>.
- Ghoraba HH, Elgouhary SM & Mansour HO (2014): Silicone oil reinjection without macular buckling for treatment of recurrent myopic macular hole retinal detachment after silicone oil removal. *J Ophthalmol* **2014**: 1–5. <https://doi.org/10.1155/2014/434272>.
- Ghosh YK, Banerjee S, Savant V, Kotamarthi V, Benson MT, Scott RAH & Tyagi AK (2004): Surgical treatment and outcome of patients with giant retinal tears. *Eye* **18**: 996–1000. <https://doi.org/10.1038/sj.eye.6701390>.
- Goezinne F, La Heij EC, Berendschot TTJM, Liem ATA & Hendrikse F (2007): Risk factors for redetachment and worse visual outcome after silicone oil removal in eyes with complicated retinal detachment. *Eur J Ophthalmol* **17**: 627–637. <https://doi.org/10.1177/112067210701700423>.
- Gonvers M & Andenmatten R. (1996): Temporary silicone oil tamponade and intraocular pressure: an 11-year retrospective study - PubMed. *Eur J Ophthalmol* **6**: 74–80. <https://pubmed.ncbi.nlm.nih.gov/8744855/>.
- Grant J & Hunter A (2006): Measuring inconsistency in knowledgebases. *J Intelligent Inform Syst* **27**: 159–184. <https://doi.org/10.1007/s10844-006-2974-4>.
- Grzybowski A & Ascaso FJ (2016): Migration of intraocular silicone oil to CNS: the role of elevated intraocular pressure and congenital optic nerve abnormalities. *Clin Neuroradiol* **26**: 127. Urban and Vogel GmbH. <https://doi.org/10.1007/s00062-015-0460-5>.
- Hammer M, Margo CE & Sanderson Grizzard W (1997): Complex retinal detachment treated with silicone oil or sulfur hexafluoride gas: a randomized clinical trial. *Ophthalmic Surg Lasers* **28**: 926–931. <https://doi.org/10.3928/1542-8877-19971101-10>.
- Hardy RJ & Thompson SG (1998): Detecting and describing heterogeneity in meta-analysis. *Stat Med* **17**: 841–856. [https://doi.org/10.1002/\(SICI\)1097-0258\(19980430\)17:8<841::AID-SIM781>3.0.CO;2-D](https://doi.org/10.1002/(SICI)1097-0258(19980430)17:8<841::AID-SIM781>3.0.CO;2-D).
- Heidenkummer HP, Kampik A & Thierfelder S (1991): Emulsification of silicone oils with specific physicochemical characteristics. *Graefes Arch Clin Exp Ophthalmol* **29**: 88–94. <https://doi.org/10.1007/BF00172269>.
- Honavar SG, Goyal M, Majji AB, Sen PK, Naduvilath T & Dandona L (1999): Glaucoma after Pars Plana Vitrectomy and Silicone Oil Injection for Complicated Retinal Detachments. *Ophthalmology* **106**: 169–177. [https://doi.org/10.1016/S0161-6420\(99\)90017-9](https://doi.org/10.1016/S0161-6420(99)90017-9).
- Hutton WL, Azen SP, Blumenkranz MS et al. (1994): The effects of silicone oil removal. Silicone Study Report 6. *Arch Ophthalmol* **112**: 778–785. <https://doi.org/10.1001/ARCHOPHT.1994.01090180076038>.
- Issa R, Xia T, Zarbin MA & Bhagat N (2020): Silicone oil removal: post-operative complications. *Eye (Basingstoke)* **34**: 537–543. <https://doi.org/10.1038/s41433-019-0551-7>.
- Jonas JB, Knorr HLJ, Rank RM & Budde WM (2001a): Intraocular pressure and silicone oil endotamponade. *J Glaucoma* **10**: 102–108. <https://doi.org/10.1097/00061198-200104000-00006>.
- Jonas JB, Knorr HL, Rank RM & Budde WM (2001b): Retinal redetachment after removal of intraocular silicone oil tamponade. *Br J Ophthalmol* **85**: 1203–1207. <https://doi.org/10.1136/bjo.85.10.1203>.
- Joussen AM, Rizzo S, Kirchhof B, Schrage N, Li X, Lente C & Hilgers RD (2011): Heavy silicone oil versus standard silicone oil in as vitreous tamponade in inferior PVR (HSO study): interim analysis. *Acta Ophthalmol* **89**: 483–489. <https://doi.org/10.1111/j.1755-3768.2011.02139.x>.
- Kakinoki M, Araki T, Iwasaki M et al. (2019): Surgical outcomes of vitrectomy for macular

- hole retinal detachment in highly myopic eyes: a multicenter study. *Ophthalmol Retina* **3**: 874–878. <https://doi.org/10.1016/j.oret.2019.04.026>.
- Kapran Z & Acar N (2007): Removal of silicone oil with 25-gauge transconjunctival sutureless vitrectomy system. *Retina* **27**: 1059–1064. <https://doi.org/10.1097/IAE.0b013e3180592c13>.
- Kapran Z, Uyar OM, Kaya V & Eltutar K (2001): Recurrences of retinal detachment after vitreoretinal surgery, and surgical approach. *Eur J Ophthalmol* **11**: 166–170. <https://doi.org/10.1177/112067210101100211>.
- Kim SW, Jaeryung OH, Yang KS, Kim MJ, Rhim JW & Huh K (2010): Risk factors for the development of transient hypotony after silicone oil removal. *Retina* **30**: 1228–1236. <https://doi.org/10.1097/IAE.0b013e3181cea661>.
- Kleinberg TT, Tzekov RT, Stein L, Ravi N & Kaushal S (2011): Vitreous substitutes: a comprehensive review. *Surv Ophthalmol* **56**: 300–323. <https://doi.org/10.1016/j.survophthal.2010.09.001>.
- Kocak I & Koc H (2013): Comparison of Densiron 68 and 1000 CSt silicone oil in the management of rhegmatogenous retinal detachment with inferior breaks. *Int J Ophthalmol* **6**: 81–84. <https://doi.org/10.3980/j.issn.2222-3959.2013.01.17>.
- la Cour M, Lux A & Heegaard S (2010): Visusminderung unter Silikon. *Klinische Monatsblätter Für Augenheilkunde* **227**: 181–184. <https://doi.org/10.1055/s-0029-1245295>.
- Lai MM, Khan N, Weichel ED & Berinstein DM (2011): Anatomic and visual outcomes in early versus late macula-on primary retinal detachment repair. *Retina* **31**: 93–98. <https://doi.org/10.1097/IAE.0b013e3181de55f0>.
- Lam RF, Cheung BTO, Yuen CYF, Wong D, Lam DSC & Lai WW (2008): Retinal redetachment after silicone oil removal in proliferative vitreoretinopathy: a prognostic factor analysis. *Am J Ophthalmol* **145**: 527–533.e2. <https://doi.org/10.1016/j.ajo.2007.10.015>.
- Lean JS, Boone DC, Azen SP, Lai MY, Linton KLP, McCuen BW & Ryan SJ (1992): Vitrectomy with silicone oil or sulfur hexafluoride gas in eyes with severe proliferative vitreoretinopathy: results of a randomized clinical trial: silicone study report 1. *Arch Ophthalmol* **110**: 770–779. <https://doi.org/10.1001/archophth.1992.01080180042027>.
- Leaver PK, Grey RHB & Garner A (1979): Silicone oil injection in the treatment of massive preretinal retraction. II. Late complications in 93 eyes. *Br J Ophthalmol* **63**: 361–367. <https://doi.org/10.1136/bjo.63.5.361>.
- Lee SH, Han JW, Byeon SH, Kim SS, Koh HJ, Lee SC & Kim M (2018): Retinal layer segmentation after silicone oil or gas tamponade for macula-on retinal detachment using optical coherence tomography. *Retina* **38**: 310–319. <https://doi.org/10.1097/IAE.0000000000001533>.
- Li M, Tang J, Jia Z et al. (2020): Long-term follow-up of primary silicone oil tamponade for retinal detachment secondary to macular hole in highly myopic eyes: a prognostic factor analysis. *Eye (Basingstoke)*. **35**: 625–631. <https://doi.org/10.1038/s41433-020-0922-0>.
- Li W, Zheng J, Zheng Q, Wu R, Wang X & Xu M (2010): Clinical complications of densiron 68 intraocular tamponade for complicated retinal detachment. *Eye* **24**: 21–28. <https://doi.org/10.1038/eye.2009.57>.
- Li X (2003): Incidence and epidemiological characteristics of rhegmatogenous retinal detachment in Beijing, China. *Ophthalmology* **110**: 2413–2417. [https://doi.org/10.1016/S0161-6420\(03\)00867-4](https://doi.org/10.1016/S0161-6420(03)00867-4).
- Lu L, Li Y, Cai S & Yang J (2002): Vitreous surgery in highly myopic retinal detachment resulting from a macular hole. *Clin Exp Ophthalmol* **30**: 261–265. <https://doi.org/10.1046/j.1442-9071.2002.00530.x>.
- Lumi X, Lužnik Z, Petrovski G, Petrovski BÉ & Hawlina M (2016): Anatomical success rate of pars plana vitrectomy for treatment of complex rhegmatogenous retinal detachment. *BMC Ophthalmol* **16**: 1–9. <https://doi.org/10.1186/s12886-016-0390-2>.
- Lyssek-Boroń A, Krysiak K, Jankowska-Szmul J, Grabarek BO, Osuch M, Kijonka M & Dobrowolski D (2019): Comparison of methods of endotamponade used during 23-gauge pars plana vitrectomy and the risk of raised intraocular pressure during 24-month follow-up: a retrospective study of 196 patients. *Med Sci Monit* **25**: 9327–9334. <https://doi.org/10.12659/MSM.918114>.
- McCuen BW, Landers MB & Machemer R (1985): The use of silicone oil following failed vitrectomy for retinal detachment with advanced proliferative vitreoretinopathy. *Ophthalmology* **92**: 1029–1034. [https://doi.org/10.1016/S0161-6420\(85\)33904-0](https://doi.org/10.1016/S0161-6420(85)33904-0).
- Mete M, Parolini B, Maggio E & Pertile G (2011): 1000 CSt silicone oil vs heavy silicone oil as intraocular tamponade in retinal detachment associated to myopic macular hole. *Graefes Arch Clin Exp Ophthalmol* **249**: 821–826. <https://doi.org/10.1007/s00417-010-1557-9>.
- Miller JB, Papakostas TD & Vavvas DG (2014): Complications of emulsified silicone oil after retinal detachment repair. *Semin Ophthalmol* **29**(5-6): 312–318. <https://doi.org/10.3109/08820538.2014.962181>.
- Mitry D, Williams L, Charteris DG, Fleck BW, Wright AF & Campbell H (2011): Population-based estimate of the sibling recurrence risk ratio for rhegmatogenous retinal detachment. *Invest Ophthalmol vis Sci* **52**: 2551–2555. <https://doi.org/10.1167/iov.10-6375>.
- Moharram HM, Abdelhalim AS, Hamid MA & Abdelkader MF (2020): Comparison between silicone oil and gas in tamponading giant retinal breaks. *Clin Ophthalmol* **14**: 127–132. <https://doi.org/10.2147/OPHT.S237783>.
- Moher D, Liberati A, Tetzlaff J & Altman DG; Altman, and The PRISMA Group (2009): Preferred reporting items for systematic reviews and meta-analyses: the PRISMA statement. *PLoS Med* **6**: e1000097. <https://doi.org/10.1371/JOURNAL.PMED.1000097>.
- Moisseiev E, Ohana O, Gershovitch L & Barak A (2013): Visual prognosis and complications following silicone oil removal. *Eur J Ophthalmol* **23**: 236–241. <https://doi.org/10.5301/ejo.5000199>.
- Morphis G, Irigoyen C, Eleuteri A, Stappeler T, Pearce I & Heimann H (2012): Retrospective review of 50 eyes with long-term silicone oil tamponade for more than 12 months. *Graefes Arch Clin Exp Ophthalmol* **250**: 645–652. <https://doi.org/10.1007/s00417-011-1873-8>.
- Moya R, Chandra A, Banerjee PJ, Tsouris D, Ahmad N & Charteris DG (2015): The incidence of unexplained visual loss following removal of silicone oil. *Eye (Basingstoke)* **29**: 1477–1482. <https://doi.org/10.1038/eye.2015.135>.
- Murat O (n.d.) “Heavy Silicone Oil vs Standard Silicone Oil for the Management of Complicated Retinal Detachment: A Prospective Randomized Study | EVRS.” Accessed November 16, 2021. <http://www.evrs.eu/heavy-silicone-oil-vs-standard-silicone-oil-for-the-management-of-complicated-retinal-detachment-a-prospective-randomized-study/>.
- Nagpal M, Jain P & Nagpal K (2012): Pars plana vitrectomy with or without silicone oil endotamponade in surgical management of endophthalmitis. *Asia Pac J Ophthalmol* **1**: 216–221. <https://doi.org/10.1097/apo.0b013e31826000cd>.
- Nakamura K, Refojo MF & Crabtree DV (n.d.) “Factors Contributing to the Emulsification of Intraocular Silicone and Fluorosilicone Oils. | IOVS | ARVO Journals.” Accessed January 20, 2021. <https://iovs.arvojournals.org/article.aspx?articleid=2199648>.
- Nakamura K, Refojo MF, Crabtree DV, Pastor J & Leong FL (1991): Ocular toxicity of low-molecular-weight components of silicone and fluorosilicone oils. *Invest Ophthalmol vis Sci* **32**: 3007–3020. <https://europepmc.org/article/med/1938278>.
- Nazir H, Wang L, Lian G, Zhu S, Zhang Y, Liu Y & Ma G (2012): Multilayered silicone oil droplets of narrow size distribution: preparation and improved deposition on hair. *Colloids Surf B* **100**: 42–49. <https://doi.org/10.1016/j.colsurfb.2012.05.018>.
- Neffendorf JE, Gupta B & Williamson TH (2018): The role of intraocular gas tamponade in rhegmatogenous retinal detachment. *Retina* **38**: S65–S72. <https://doi.org/10.1097/IAE.0000000000002015>.
- Nguyen QH, Lloyd MA, Heuer DK, Baerveldt G, Minckler DS, Lean JS & Liggett PE (1992): Incidence and management of glaucoma after intravitreal silicone oil injection for complicated retinal detachments. *Ophthalmology* **99**: 1520–1526. [https://doi.org/10.1016/S0161-6420\(92\)31771-3](https://doi.org/10.1016/S0161-6420(92)31771-3).
- Ni Y, Fang H, Zhang X, Lin XF & Guo WJ (2019): Analysis of the causative factors related to earlier emulsification of silicone oil. *Int J Ophthalmol* **12**: 517–519. <https://doi.org/10.18240/ijo.2019.03.25>.
- Oh HJ, Chang W & Sagong M (2015): Efficacy and safety of active silicone oil removal through a 23-gauge transconjunctival cannula using an external vacuum pump. *Int J Ophthalmol* **8**: 347–352. <https://doi.org/10.3980/j.issn.2222-3959.2015.02.24>.

- Okamoto F, Sugiura Y, Okamoto Y, Hiraoka T & Oshika T (2013): Changes in contrast sensitivity after surgery for macula-on rhegmatogenous retinal detachment. *Am J Ophthalmol* **156**: 667–672.e1. <https://doi.org/10.1016/j.ajo.2013.05.017>.
- Ozdek S, Yuksel N, Gurelik G & Hasanreisoglu B (2011): High-density silicone oil as an intraocular tamponade in complex retinal detachments. *Can J Ophthalmol* **46**: 51–55. <https://doi.org/10.3129/i10-107>.
- Pastor JC, Puente B, Telleria J, Carrasco B, Sánchez H & Nocito M (2001): Antisilicone antibodies in patients with silicone implants for retinal detachment surgery. *Ophthalmic Res* **33**: 87–90. <https://doi.org/10.1159/000055649>.
- Pastor JC, Zarco JM, Del Nozal MJ, Pampliega A & Marinero P (1998): Clinical consequences of the use of highly purified silicone oil: comparative study of highly and less purified silicone oil. *Eur J Ophthalmol* **8**: 179–183. <https://doi.org/10.1177/112067219800800311>.
- Pastor Jimeno JC, de la Rúa ER, Fernández Martínez I, del Nozal Nalda MJ & Jonas JB (2007): Lipophilic substances in intraocular silicone oil. *Am J Ophthalmol* **143**: 707–709. <https://doi.org/10.1016/j.ajo.2006.11.015>.
- Pavlovic S, Dick B, Schmidt KG, Tomic Z & Latinovic S (1995): Long-term outcome after silicone oil removal. *Ophthalmology* **92**: 672–676.
- Pertile G & Claes C (1999): Silicone oil vs. gas for the treatment of full-thickness macular hole. *Bull Soc Belge D'ophtalmol* **274**: 31–36.
- Post-Vitreotomy Cataract Acceleration in Phakic Eyes: A Review - Khusbu Keyal - Discovery Medicine. (n.d.) Accessed May 23, 2021. <https://www.discoverymedicine.com/Khusbu-Keyal-2/2017/12/post-vitreotomy-cataract-acceleration-in-phakic-eyes-a-review/>.
- Ratanapakorn T, Thongmee W, Meethongkam K, Sinawat S, Sanguansak T, Bhoombunchoo C, Laovirojjanakul W & Yospaiboon Y (2020): Emulsification of different viscosity silicone oil in complicated retinal detachment surgery: a randomized double-blinded clinical trial. *Clin Ophthalmol* **14**: 359–367. <https://doi.org/10.2147/OPTH.S242804>.
- Review Manager (RevMan) [Computer Program]. 2014. Copenhagen: The Nordic Cochrane Centre; The Cochrane Collaboration.
- Rhatigan M, McElnea E, Murtagh P, Stephenson K, Harris E, Connell P & Keegan D (2018): Final anatomic and visual outcomes appear independent of duration of silicone oil intraocular tamponade in complex retinal detachment surgery. *Int J Ophthalmol* **11**: 83–88. <https://doi.org/10.18240/ijo.2018.01.15>.
- Rodriguez M, Lin J, Townsend JH, Smiddy WE, Albini TA, Berrocal AM, Sridhar J & Flynn HW (2018): Giant retinal tears: clinical features and outcomes of vitreoretinal surgery at a university teaching hospital (2011–2017). *Clin Ophthalmol* **12**: 2053–2058. <https://doi.org/10.2147/OPTH.S180353>.
- Romano MR, Angi M, Romano V, Parmeggiani F, Campa C, Valldeperas X & Costagliola C (2010): Intraocular pressure changes following the use of silicone oil or Densiron® 68 as endotamponade in pars plana vitrectomy. *Clin Ophthalmol* **4**: 1391–1396. <https://doi.org/10.2147/OPTH.S14252>.
- Saleh OA, Fleissig E & Barr CC (2020): Outcomes after the use of silicone oil in complex retinal detachment repair. *J VitreoRetinal Dis* **4**: 96–102. <https://doi.org/10.1177/2474126419896658>.
- Scheerlinck LM, Schellekens PA, Liem AT, Steijns D & Van Leeuwen R (2016): Incidence, risk factors, and clinical characteristics of unexplained visual loss after intraocular silicone oil for macula-on retinal detachment. *Retina* **36**: 342–350. <https://doi.org/10.1097/IAE.0000000000000711>.
- Scheerlinck LM, Schellekens PA, Liem AT, Steijns D & van Leeuwen R (2018): Retinal sensitivity following intraocular silicone oil and gas tamponade for rhegmatogenous retinal detachment. *Acta Ophthalmol* **96**: 641–647. <https://doi.org/10.1111/aos.13685>.
- Schmidt JC, Rodrigues EB, Hoerle S, Meyer CH & Kroll P (2003): Primary vitrectomy in complicated rhegmatogenous retinal detachment - a survey of 205 eyes. *Ophthalmologica* **217**: 387–392. <https://doi.org/10.1159/000073067>.
- Scholda C, Egger S, Lakits A & Haddad R (1997): Silicone oil removal: results, risks and complications. *Acta Ophthalmol Scand* **75**: 695–699. <https://doi.org/10.1111/j.1600-0420.1997.tb00633.x>.
- Scholda C, Egger S, Lakits A, Walch K, Von Eckardstein E & Biowski R (2000): Retinal detachment after silicone oil removal. *Acta Ophthalmol Scand* **78**: 182–186. <https://doi.org/10.1034/j.1600-0420.2000.078002182.x>.
- Schwartz SG, Flynn HW, Lee WH & Wang X (2014): Tamponade in surgery for retinal detachment associated with proliferative vitreoretinopathy. *Cochrane Database Syst Rev* **2014**. <https://doi.org/10.1002/14651858.CD006126.pub3>.
- Schwartz SG, Flynn HW, Wang X, Kuriyan AE, Abariga SA & Lee WH (2020): Tamponade in surgery for retinal detachment associated with proliferative vitreoretinopathy. *Cochrane Database Syst Rev* **2020**. <https://doi.org/10.1002/14651858.CD006126.pub4>.
- Scott IU, Flynn HW, Azen SP, Lai MY, Schwartz S & Trese MT (1999): Silicone oil in the repair of pediatric complex retinal detachments: a prospective, observational, multicenter study. *Ophthalmology* **106**: 1399–1408. [https://doi.org/10.1016/S0161-6420\(99\)00731-9](https://doi.org/10.1016/S0161-6420(99)00731-9).
- Scott IU, Flynn HW, Murray TG, Smiddy WE, Davis JL & Feuer WJ (2005): Outcomes of complex retinal detachment repair using 1000- vs 5000-centistoke silicone oil. *Arch Ophthalmol* **123**: 473–478. <https://doi.org/10.1001/archoph.123.4.473>.
- Semeraro F, Russo A, Morescalchi F, Gambicorti E, Vezzoli S, Parmeggiani F, Romano MR & Costagliola C (2019): Comparative assessment of intraocular inflammation following standard or heavy silicone oil tamponade: a prospective study. *Acta Ophthalmol* **97**: e97–e102. <https://doi.org/10.1111/aos.13830>.
- Shah CP, Ho AC, Regillo CD, Fineman MS, Vander JF & Brown GC (2008): Short-term outcomes of 25-gauge vitrectomy with silicone oil for repair of complicated retinal detachment. *Retina* **28**: 723–728. <https://doi.org/10.1097/IAE.0b013e318166976d>.
- Sharma T, Gopal L, Shanmugam MP, Bhende PS, Agrawal R, Badrinath SS & Samanta TK (2002): Management of recurrent retinal detachment in silicone oil-filled eyes. *Retina* **22**: 153–157. <https://doi.org/10.1097/00006982-200204000-00003>.
- Soheilian M, Mazareei M, Mohammadpour M & Rahmani B (2006): Comparison of silicon oil removal with various viscosities after complex retinal detachment surgery. *BMC Ophthalmol* **6**: 1–6. <https://doi.org/10.1186/1471-2415-6-21>.
- Song ZM, Chen D, Ke ZS, Wang RH, Wang QM, Fan LU & Jia QU (2010): A new approach for active removal of 5,000 centistokes silicone oil through 23-gauge cannula. *Retina* **30**: 1302–1307. <https://doi.org/10.1097/IAE.0b013e3181e09841>.
- Stang A (2010): Critical evaluation of the newcastle-ottawa scale for the assessment of the quality of nonrandomized studies in meta-analyses. *Eur J Epidemiol* **25**: 603–605. <https://doi.org/10.1007/s10654-010-9491-z>.
- Tabandeh H, Flaxel C, Sullivan PM, Leaver PK, Flynn HW & Schiffman J (2000): Scleral rupture during retinal detachment surgery: risk factors, management options, and outcomes. *Ophthalmology* **107**: 848–852. [https://doi.org/10.1016/S0161-6420\(00\)00033-6](https://doi.org/10.1016/S0161-6420(00)00033-6).
- Tafoya ME, Michael Lambert H, Lani VU & Ding M (2003): Visual outcomes of silicone oil versus gas tamponade for macular hole surgery. *Semin Ophthalmol* **18**: 127–131. <https://doi.org/10.1076/soph.18.3.127.29808>.
- Tavares RL, Pinho DE, Nóbrega MJ, Nóbrega FAJ, Novelli FJD & Oliveira CACD (2015): Timing and outcomes after silicone oil removal in proliferative vitreoretinopathy: a retrospective clinical series. *Int J Retina Vitreous* **1**: 2–6. <https://doi.org/10.1186/s40942-015-0002-y>.
- Tayyab H, Khan AA & Javaid RMM (2017): Clinical outcome of 23g trans-conjunctival pars plana vitrectomy: a prospective comparison of phaco-vitreotomy with only vitrectomy in phakic eyes. *Pakistan J Med Sci* **33**: 1123–1127. <https://doi.org/10.12669/pjms.335.13430>.
- Titiyal JS, Agarwal E, Angmo D, Sharma N & Kumar A (2017): Comparative evaluation of outcomes of phacoemulsification in vitrectomized eyes: silicone oil versus air/gas group. *Int Ophthalmol* **37**: 565–574. <https://doi.org/10.1007/s10792-016-0305-5>.
- Tognetto D, Minutola D, Sanguineti G & Ravalico G (2005): Anatomical and functional outcomes after heavy silicone oil tamponade in vitreoretinal surgery for complicated retinal detachment: a pilot study. *Ophthalmology* **112**:

- 1574.e1–1574.e8. <https://doi.org/10.1016/j.optha.2005.04.013>.
- Toklu Y, Cakmak HB, Ergun SB, Yorgun MA & Simsek S (2012): Time course of silicone oil emulsification. *Retina* **32**: 2039–2044. <https://doi.org/10.1097/IAE.0b013e3182561f98>.
- Valone J & McCarthy M (1994): Emulsified anterior chamber silicone oil and glaucoma. *Ophthalmology* **101**: 1908–1912. [https://doi.org/10.1016/S0161-6420\(94\)31084-0](https://doi.org/10.1016/S0161-6420(94)31084-0).
- Wolf S, Schön V, Meier P & Wiedemann P (2003): Silicone oil-RMN3 mixture ('heavy silicone oil') as internal tamponade for complicated retinal detachment. *Retina* **23**: 335–342. <https://doi.org/10.1097/00006982-200306000-00008>.
- Wong D, Kumar I, Quah SA, Ali H, Valdeperas X & Romano MR (2009): Comparison of post-operative intraocular pressure in patients with densiron-68 vs conventional silicone oil: a case-control study. *Eye* **23**: 190–194. <https://doi.org/10.1038/sj.eye.6703055>.
- Wong D, Van Meurs JC, Stappler T, Groenewald C, Pearce IA, McGalliard JN, Manousakis E & Herbert EN (2005): A pilot study on the use of a perfluorohexyloctane/silicone oil solution as a heavier than water internal tamponade agent. *Br J Ophthalmol* **89**: 662–665. <https://doi.org/10.1136/bjo.2004.055178>.
- Yang CM, Pei Yuang SU, Yeh PT & Chen MS (2008): Combined rhegmatogenous and traction retinal detachment in proliferative diabetic retinopathy: clinical manifestations and surgical outcome. *Can J Ophthalmol* **43**: 192–198. <https://doi.org/10.3129/I08-007>.
- Yaşa D & Alkın Z (2018): Comparison of outcomes for traumatic retinal detachment surgery using 1000- or 5000-centistoke silicone oil. *Saudi J Ophthalmol* **32**: 286–289. <https://doi.org/10.1016/j.sjopt.2018.09.003>.
- Yorgun MA, Toklu Y, Mutlu M & Ozen U (2016): Clinical outcomes of 25-gauge vitrectomy surgery for vitreoretinal diseases: comparison of vitrectomy alone and phacovitrectomy. *Int J Ophthalmol* **9**: 1163–1169. <https://doi.org/10.18240/ijo.2016.08.13>.
- Zafar S, Shakir M, Mahmood SA, Amin S & Iqbal Z (2016): Comparison of 1000-centistoke versus 5000-centistoke silicone oil in complex retinal detachment surgery. *J Coll Physicians Surg Pak* **26**: 36–40.
- Zhu XJ, Zhang KK, Zhou P, Jiang CH & Yi LU (2015): AA-crystallin gene CpG islands hypermethylation in nuclear cataract after pars plana vitrectomy. *Graefes Arch Clin Exp Ophthalmol* **253**: 1043–1051. <https://doi.org/10.1007/s00417-015-2949-7>.

Received on February 19th, 2021.

Accepted on October 25th, 2021.

Correspondence:

Salvador Pastor-Idoate, MD, PhD, FEBO
 Department of Ophthalmology
 University Clinical Hospital of Valladolid
 Ramón y Cajal Avenue N° 3, 47003
 Phone: +0034 690179835
 Email: pastori@ioba.med.uva.es
 Ricardo Usategui-Martín, Biol, PhD
 Institute of Applied Ophthalmobiology
 (IOBA)
 University of Valladolid
 Ramón y Cajal Avenue N° 3, 47003
 Valladolid, Spain
 Email: rusateguim@ioba.med.uva.es
 Phone: +0034 617720682

Supporting Information

Additional Supporting Information may be found in the online version of this article:

Table S1 Study quality assessment by the Newcastle-Ottawa Assessment Scale.

Table S2 Risk of bias assessment by the Cochrane Collaboration's tool.

Table S3 Pathologies of the subjects analysed in each study included in the meta-analysis.