

● PERSPECTIVE

## Ocular findings in Zucker Diabetic Fatty rats emphasize the key role of neuroglia degeneration in diabetic retinopathy pathophysiology

Diabetes mellitus is a leading cause of acquired vision loss and one of the world's fastest growing chronic diseases. Diabetic retinopathy (DR), a specific complication of chronic hyperglycemia, is the leading cause of acquired vision loss worldwide in middle-aged and therefore economically active people that also increases the medical and economic burden on the society (Klein, 2007). The natural history of DR has been divided into two clinical stages based on the proliferative status of the retinal vasculature: an early, non-proliferative stage and an advanced, proliferative or neovascular stage. Although DR has been regarded as a vascular disorder for many years, neuroglial abnormalities have also been recognized and are still being explored to determine their clinical significance. A lot of important information or clues on the development of DR can be obtained from human studies; however, the complete mechanisms of DR development have not yet been elucidated. In this sense, diabetic rat models are playing key roles in elucidating the pathogenesis of human diabetes and its complications, such as nephropathy, retinopathy, and neuropathy. Although spontaneous diabetic rat models are well characterized in terms of retina-choroid vascular modifications, changes in retinal cells (neurons and glia) associated with hyperglycemia have not been studied in detail on most available models (Lai and Lo, 2013; Olivares et al., 2017). Early structural gliotic reactions were initially described in pharmacologically induced rat models of diabetes (Rungger-Brändle et al., 2000). Recently, neuroglial morphologic degenerative changes have been described in spontaneous diabetic Zucker Diabetic Fatty (ZDF) rats prior to changes in vasculature appearance (Fernandez-Bueno et al., 2017). The ocular findings observed in animal models of diabetes, such as the ZDF rats, emphasize that DR is not, at least initially, a primary vascular disorder and that prolonged damage to the neural and glial components of the retina plays a key role in the development of the disease.

As a model of human disease, the rat offers some advantages over other species. Rats are the most widely used animals in medical research, because rat and human physiology are very similar. The size of the animal enhances its use as a disease model, and anatomical and physiological similarity of important organs allows extrapolation of how the organ responds to an experimental lesion and the effects of drug administration. Furthermore, 90% of rat genes have orthologs in the human genome (Mullins and Mullins, 2004). The use of rats as an experimental model in ophthalmology is very common due to multiple advantages, such as a relatively large eyeball, which allows to carry out functional, morphological and molecular analyses. Rat models of diabetes resemble human pathophysiology in important ways, including the ability of external agents (e.g., diet, stress and toxins) to modify the disease. Rodents are the most commonly used models for studying DR. However, rodents do not have a fovea and some manifestations of DR, such as diabetic macular edema, cannot be reproduced in rodent models. Dogs develop similar morphological retinal lesions as those seen in humans, and pigs and zebrafish have similar vasculature and retinal structures to humans (Olivares et al., 2017).

To have a better understanding of the development of DR at the molecular and cellular levels, a variety of diabetic rat models have been studied. The most useful diabetic rat models are those that spontaneously develop the disease. There are six genetic rat models of DR: biobreeding (BB), Otsuka long-evans Tokushima fatty (OLETF), ZDF, Wistar Bonn/Kobori (WBN/Kob), Goto-Ka-

kizaki (GK), and spontaneously diabetic Torii (SDT). The BB, OLETF, and ZDF are monogenic models of DR with independent mutations that perturb different nodes of the DR disease pathway. The WBN/Kob, GK, and SDT models, in contrast, are polygenic models. Although ocular vessel degeneration is profoundly characterized in these models, few examinations have studied the retina neuroglia modifications associated with hyperglycemia in detail.

- The BB rats spontaneously develop polygenic autoimmune type 1 diabetes, in which the pancreatic  $\beta$ -cells were selectively destroyed. Although progressive cellular modifications of the microvasculature were reported after 2 months of hyperglycemia (Sima et al., 1985), changes in the retinal neuroglia were not described in the literature.

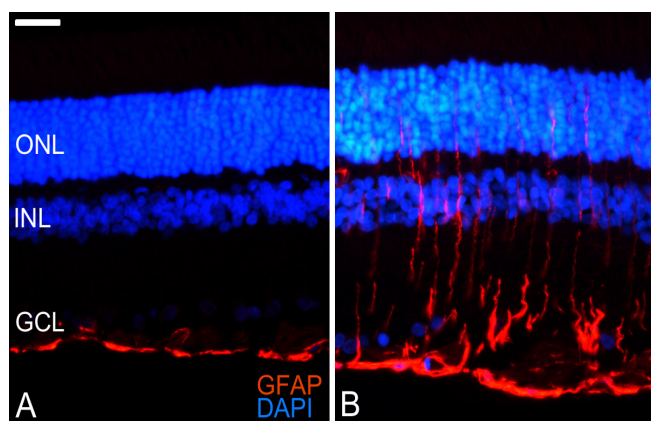
- The OLETF rats, another type 2 diabetic rat model, show elevated blood glucose from 5 months of age. By 14 months of hyperglycemia, the inner nuclear layer and the photoreceptor layer became thinner, accompanied with modifications of the retinal pigment epithelium cells (Lu et al., 2003). Vascular modifications were observed after 6 months of hyperglycemia. The late onset of diabetes and the related symptoms diminish the popularity of using this model to study DR.

- The WBN/Kob rats are a type 2 diabetes model related to endo-exocrine pancreatic insufficiency, and only male offspring develop diabetic symptoms. The animal becomes hyperglycemic at around 9–12 months of age; however, thickness of the photoreceptor outer segments and the outer nuclear layer were reduced at 5 months of age (before hyperglycemia). About 2 months after becoming hyperglycemic, these rats also showed reduction in the visual cells, the outer plexiform layer, and the retinal thickness (Miyamura and Amemiya, 1998). Progressive vascular lesions were identified from 1 month of hyperglycemia. Although this rat model presents neuronal degeneration, its early onset (before hyperglycemia) suggests that the etiology of retinal degeneration may not be the same as that in humans; therefore, it is not considered an adequate model to study DR.

- The GK rats are a spontaneous model of non-insulin-dependent diabetes without obesity. These rats are originated from normal Wistar rats, and they were selected *via* repeated inbreeding exercises using glucose intolerance as a selection index. Rats at 4–6 weeks of age develop hyperglycemia and, 1 month later, changes in the vasculature of the retina begin to be observed (Miyamoto et al., 1996). There are only limited publications about the retinal pathophysiology of these rats and characterization of the non-vascular-related lesions was not described in the literature.

- The SDT rats are another model of non-obese type 2 diabetes. Hyperglycemia is observed in the male SDT rats at 5 months of age. Retinal dysfunction was observed by electroretinography from 4 weeks of hyperglycemia. At the same time, the number of apoptotic cells in the retina was increased, along with vascular degenerations (Kakehashi et al., 2006). Advanced lesions of the retina, such as neovascularization and tractional retinal detachment with fibrous proliferation, can be detected after more than 48 weeks of hyperglycemia (Kakehashi et al., 2006). Therefore, the SDT rat seems to be an adequate model to specifically study the proliferative form of DR.

- Finally, the ZDF rats are a genetic model of type 2 diabetes that carry an inherited mutation of the *fa/fa* gene, which leads to a phenotype of insulin resistance and results in glucose intolerance. Hyperglycemia starts at 6–7 weeks of age and is high throughout their lifespan. Capillary modifications were observed at 5 months of hyperglycemia, followed by apoptosis of vascular cells at 6 months. However, prior to the appearance of these vascular changes at 15 weeks of hyperglycemia, several modifications in the retinal cells (neurons and glia) have been recently reported (Fernandez-Bueno et al., 2017). At the time of this study, ZDF rat's retinas present enclosed retinal regions with morphological degenerative changes. The thickness of the neuroretina significantly increases, and the number of nuclei in the nuclear layers decreases, with a higher number of terminal deoxynucleotidyl transferase dUTP nick end



**Figure 1** Glial cell activation in Zucker Diabetic Fatty (ZDF) rats at 15 weeks of hyperglycemia.

Glial fibrillary acidic protein (GFAP; red) immunofluorescence in retina sections from lean (A) and ZDF (B) rats. In lean animals, GFAP is limited to the innermost layers of the neuroretina, while ZDF rats show massive GFAP upregulation throughout the cytoplasm of the Müller cells to the outer nuclear layer (ONL). GFAP upregulation is the most sensitive non-specific response to retinal disease and injury. DAPI: 4',6-Diamino-2-phenylindole dihydrochloride (blue; cell nuclei); GCL: ganglion cell layer; INL: inner nuclear layer. Scale bar: 25  $\mu$ m.

labeling (TUNEL)-positive elements (apoptotic cell marker). ZDF rats show upregulation of the reactive gliosis markers, fibrillary acidic protein (GFAP; **Figure 1**), and vimentin. The upregulation of GFAP within the Müller cells (retina glial cells) is a remarkably ubiquitous response in retinal pathology and the most sensitive non-specific response to retinal disease and injury. Therefore, early GFAP overexpression indirectly indicates retinal injury, Müller cell activation, and secondary degenerative processes in the retina. Furthermore, changes in the expression of proteins related to the proper functioning of the retinal glia, such as glutamate-aspartate transporter (GLAST) and advanced glycation end products (AGEs), can also provide the early molecular pathogenic mechanisms responsible for neuroglial reactions in DR. Although no detectable differences in photoreceptor cellular morphology and retinal pigment epithelium cells were described (Fernandez-Bueno et al., 2017), functional impairment of the inner retina was reported in ZDF rats from 6 weeks of hyperglycemia (Johnson et al., 2013). Further studies using electron microscopy or protein quantification assays can reveal early changes in visual cells. Therefore, the ZDF rat is thought to be useful for pharmacological intervention studies because it is naturally and severely type 2 diabetic, and same-sex littermates can be used as controls. In addition, the described pathological findings demonstrate that the ZDF rat is a suitable model for studying DR early pathophysiology.

As DR is a complex disease with genetic and environmental influences, animal models are developed by induction or genetic mutation using breeding and gene editing techniques. Rodent models are most often studied, as their small size, short life span, and fast breeding rates allow for the most efficient studies. Unfortunately, there is no single animal model that displays all the clinical features of DR as seen in humans from the very early cellular and vascular abnormalities to the proliferative stages. However, early retinal pathological features observed in diabetic rat models, such as ZDF rats, present suitable targets for future therapeutic investigations for the treatment of DR to reduce the progressive loss of vision in patients. The importance of adequately characterized diabetic rat models will be a constant in the future, and their use will be indispensable to better understanding the pathophysiology of diabetes complications and to evaluate the effect of the new drugs properly; however, differences between animal models and human must be kept in mind.

This study was supported by EU Program FP7-PEOPLE-2013-IAPP (612218/3D-NET) and FEDER-CICYT MAT2013-47501-CO2-1-R (Ministry of Economy and Competitiveness, Spain) Grants. IF-B was supported by RETICS (RD12/0034/0001), Instituto de Salud Carlos III, Spain.

This study was partially presented at the ARVO Annual Meeting, May 2016, Seattle, Washington, USA.

**Ivan Fernandez-Bueno**\*, Yolanda Diebold

Instituto Universitario de Oftalmobiología Aplicada, University of Valladolid, Valladolid, Spain (Fernandez-Bueno I, Diebold Y) Red Temática de Investigación Cooperativa en Salud (RETICS), Oftared, Instituto de Salud Carlos III, Madrid, Spain (Fernandez-Bueno I)

Biomedical Research Networking Center on Bioengineering, Biomaterials and Nanomedicine, CIBER-BBN, Valladolid, Spain (Diebold Y)

\*Correspondence to: Ivan Fernandez-Bueno, DVM, Ph.D., ifernandezb@ioba.med.uva.es.

orcid: 0000-0003-3380-4040 (Ivan Fernandez-Bueno)

Accepted: 2018-01-20

doi: 10.4103/1673-5374.226391

Plagiarism check: Checked twice by iThenticate.

Peer review: Externally peer reviewed.

Open access statement: This is an open access article distributed under the terms of the Creative Commons Attribution-NonCommercial-ShareAlike 3.0 License, which allows others to remix, tweak, and build upon the work non-commercially, as long as the author is credited and the new creations are licensed under identical terms.

## References

- Fernandez-Bueno I, Jones R, Soriano-Romani L, López-García A, Galvin O, Cheetham S, Diebold Y (2017) Histologic characterization of retina neuroglia modifications in diabetic Zucker diabetic fatty rats. *Invest Ophthalmol Vis Sci* 58:4925-4933.
- Johnson LE, Larsen M, Perez MT (2013) Retinal adaptation to changing glycemic levels in a rat model of type 2 diabetes. *PLoS One* 8:e55456.
- Kakehashi A, Saito Y, Mori K, Sugi N, Ono R, Yamagami H, Shinohara M, Tamemoto H, Ishikawa SE, Kawakami M, Kanazawa Y (2006) Characteristics of diabetic retinopathy in SDT rats. *Diabetes Metab Res Rev* 22:455-461.
- Klein BE (2007) Overview of epidemiologic studies of diabetic retinopathy. *Ophthalmic Epidemiol* 14:179-183.
- Lai AK, Lo AC (2013) Animal models of diabetic retinopathy: summary and comparison. *J Diabetes Res* 2013:106594.
- Lu ZY, Bhutto IA, Amemiya T (2003) Retinal changes in Otsuka long-evans Tokushima Fatty rats (spontaneously diabetic rat)--possibility of a new experimental model for diabetic retinopathy. *Jpn J Ophthalmol* 47:28-35.
- Miyamoto K, Ogura Y, Nishiwaki H, Matsuda N, Honda Y, Kato S, Ishida H, Seino Y (1996) Evaluation of retinal microcirculatory alterations in the Goto-Kakizaki rat. A spontaneous model of non-insulin-dependent diabetes. *Invest Ophthalmol Vis Sci* 37:898-905.
- Miyamura N, Amemiya T (1998) Lens and retinal changes in the WBN/Kob rat (spontaneously diabetic strain). *Electron-microscopic study. Ophthalmic Res* 30:221-232.
- Mullins LJ, Mullins JJ (2004) Insights from the rat genome sequence. *Genome Biol* 5:221.
- Olivares AM, Althoff K, Chen GF, Wu S, Morrisson MA, DeAngelis MM, Haider N (2017) Animal models of diabetic retinopathy. *Curr Diab Rep* 17:93.
- Rungger-Brändle E, Dosso AA, Leuenberger PM (2000) Glial reactivity, an early feature of diabetic retinopathy. *Invest Ophthalmol Vis Sci* 41:1971-1980.
- Sima AA, Chakrabarti S, Garcia-Salinas R, Basu PK (1985) The BB-rat--an authentic model of human diabetic retinopathy. *Curr Eye Res* 4:1087-1092.