

Research article

Hair cortisol level as a molecular biomarker in retinitis pigmentosa patients

M. Mateos-Olivares^{a,b,1}, E.M. Sobas^{b,1}, K. Puertas-Neyra^b, M.I. Peralta-Ramírez^c,
R. González-Pérez^{d,e}, J. Martín-Vallejo^f, C. García-Vázquez^b, R.M. Coco^{b,g,2}, J.C. Pastor^{a,b,g,2},
S. Pastor-Idoate^{a,b,g,2,*}, R. Usategui-Martín^{b,g,h,2,**}

^a Department of Ophthalmology, Hospital Clínico Universitario de Valladolid, Valladolid, Spain

^b Institute of Applied Ophthalmobiology (IOBA), University of Valladolid, Valladolid, Spain

^c Mind, Brain, and Behavior Research Center (CIMCYC), Faculty of Psychology, University of Granada, Granada, Spain

^d Department of Pharmacology, CIBERehd, School of Pharmacy, Instituto de Investigación Biosanitaria ibs, GRANADA, University of Granada, Granada, Spain

^e Centro de Investigación Biomédica en Red de Enfermedades Hepáticas y Digestivas (CIBERehd), Instituto de Salud Carlos III, Madrid, Spain

^f Department of Statistics, University of Salamanca, Salamanca, Spain

^g Cooperative Health Network for Research in Ophthalmology (Oftared), National Institute of Health Carlos III, ISCIII, Madrid, Spain

^h Department of Cell Biology, Histology and Pharmacology, School of Medicine, University of Valladolid, Valladolid, Spain



ARTICLE INFO

Keywords:

Retinitis pigmentosa

Hair cortisol concentration

Negative psychological states

Chronic stress

Variations in vision

ABSTRACT

Purpose: Retinitis pigmentosa (RP) patients commonly experience negative psychological states due to their progressive and unpredictable loss of vision and visual variations related to stress. The aim of this study was to examine hair cortisol concentrations (HCCs), which is usually associated with chronic stress, pretending to unveil possible associations between underlying psychological factors and disease severity in RP patients.

Methods: Seventy-eight RP patients and 148 healthy controls were included in this study. A complete ophthalmological exam was performed in all patients to grade into severity disease groups. Perceived stress and trait-anxiety were measured by the State-Trait Anxiety Inventory (STAI) questionnaire.

Results: Fifty-two (67%) patients had severe RP and 26 (33%) mild-moderate RP. Fifty-eight (58,9%) patients reported severely levels of stress and 18 (23,1%) highly levels assessed by STAI questionnaire. RP patients exhibited higher HCCs (500.04 ± 120.99 pg/mg) than in controls (136.17 ± 60.51 pg/mg; $p < 0.001$). Severe RP patients had significant higher HCCs than mild-moderate patients differing in 274.27 pg/mg ($p < 0.001$). RP severity grade and perceived anxiety levels in the questionnaires were not associated. Group differences were not affected by relevant covariates (age, grade of severity, stress status, and gender).

Conclusions: HCC seems an effective biomarker associated with chronic stress in RP patients. This study shows that HCC in patients with RP are elevated compared to population-based controls, and association between HCC and RP severity was found. Future research is needed to characterize the effect of untreated negative psychological states on progression of the disease if any.

1. Introduction

Retinitis pigmentosa (RP) is the name given to a group of hereditary degenerative retinal disorders where the progressive decrease of photoreceptors results in severe visual impairment and irreversible blindness (Hamel, 2006; Hartong et al., 2006; Parmeggiani et al., 2011). Despite RP is considered as a rare disease, it is the commonest inherited retinal

dystrophy affecting approximately one in 4000 people worldwide (Galan et al., 2011; Hartong et al., 2006; Mifsud and Reul, 2018).

Most RP patients continuously face a slowly progressive loss of vision for which there is no currently available cure although advances are being made in gene therapy for some mutations (RPE65). This can result in an inexorable threat to patients' independence and development of negative psychological states. It is well known that RP patients are at

* Corresponding author. IOBA-University of Valladolid, Paseo de Belén, 17, 47011, Valladolid, Spain.

** Corresponding author. IOBA-University of Valladolid, Paseo de Belén, 17, 47011, Valladolid, Spain.

E-mail addresses: pastoridoate.salvador@gmail.com (S. Pastor-Idoate), rusategui@gmail.com (R. Usategui-Martín).

¹ These authors have contributed equally to this work.

² Members of an Affiliated Center of the European Reference Network in Ophthalmology (ERN-EYE).

high risk for stress as their vision loss progresses (Bittner et al., 2010; Kiser and Dagnelie, 2008; Prem Senthil et al., 2017). But it has also been reported that variations in vision in RP patients are often related to stress and that vision partially improved when stress was alleviated (Kiser and Dagnelie, 2008).

The first symptom of RP is generally nyctalopia or loss of night vision with progressive narrowing of the visual fields. Over time, depending on the severity and rate of progression, complete central vision loss and photopsia can be the result, as a late effect of the disease. In addition, as the disease progresses other features may develop including color vision impairments, day-to-day fluctuations in vision, and photophobia which can severely impair a patient's quality of life and affect their ability to perform daily activities, increasing the risk of being stressed and anxious (Heckenlively et al., 1988; O'Neal and Luther, 2021; Otsuka et al., 2020).

The stress response is mainly mediated by the activation of two pathways: the sympathetic adrenomedullary system (SAS), in which catecholamines are secreted, and the hypothalamic-pituitary-adrenal (HPA) axis whose end-up hormones are glucocorticoids, such as cortisol (King and Hegadoren, 2002; Mifsud and Reul, 2018; Russell et al., 2012). Acute stress is primarily assessed using catecholamines as biomarkers, whereas subacute and chronic stress can be evaluated measuring the activity of the HPA axis through cortisol release (Davenport et al., 2006; Gow et al., 2010; Russell et al., 2012).

Cortisol, considered a key component of the physiological stress response, is the most widely used biomarker of stress (Davenport et al., 2006; Russell et al., 2012). Its levels could be measured in saliva, blood, urine, and feces samples, but those revealed high variability, as they are influenced by numerous factors providing less reliable information about the long-term glucocorticoid exposure due to HPA chronic activation (Adam et al., 2006; Davenport et al., 2006; Garcia-Leon et al., 2019; Gibson et al., 1999; Karlén et al., 2011; Wolfram et al., 2013).

By contrast, recent studies have validated the analysis of hair cortisol concentrations (HCC) as a long-term systematic stress biomarker (Staufenbiel et al., 2013). HCC provides a "window to the past" in terms of cortisol levels. Considering that bioactive cortisol accumulates in growing hair and the average hair growth per month is 1 cm, it is accepted that HCC reflects the cortisol secretion over a period of months (Davenport et al., 2006; Garcia-Leon et al., 2019; Russell et al., 2012; Wennig, 2000). Moreover, HCC determined from hair strands collected near the scalp is a non-invasive and painless methodology.

The use of HCC as a biomarker in ocular diseases has been previously reported in recent studies (Lenk et al., 2017, 2019; van Haalen et al., 2020). In patients with active central serous chorioretinopathy (CSC) or keratoconus, HCC analysis revealed increased values, supporting the idea that cortisol may be a useful tool to monitor disease activity or progression (Lenk et al., 2017, 2019). However, to the best of our knowledge, HCC has not been previously studied in RP patients.

In the current study, we evaluated HCC in a large cohort of patients with RP, comparing their HCC values with a control group. In addition, we investigated the suspected relationship between cortisol values, the degree of anxiety-stress status and RP severity grades.

2. Materials and methods

2.1. Study design and participants

In this observational study, RP patients were recruited from RECYL (Association of RP patients from Castilla y León, Spain) and two study groups were formed, the RP group ($n = 78$) and a second group of healthy controls ($n = 148$). Participants were examined between January 2019 and June 2021 at the Department of Ophthalmology of Clinical University Hospital of Valladolid and Institute of Applied Ophthalmobiology (IOBA, Eye Institute), University of Valladolid, Valladolid, Spain. The study protocol was approved by the Medical Ethics Committee of Clinical University Hospital of Valladolid and all research

done followed the Tenets of the Declaration of Helsinki. Written consent was obtained from each participant before examinations.

The control group was formed to obtain reference values for normal hair cortisol values and comprised healthy subjects without history of retinal diseases.

The inclusion criteria in the RP group were: 1) RP diagnose, 2) age from 18 to 60, and (3) to be Caucasian. The exclusion criteria for all groups were: (1) presence of other retinal pathologies, (2) a history of ocular surgery at least 6 months before, (3) uveitis or glaucoma, (4) a history of severe mental illness, (5) patients with inflammatory or autoimmune diseases, (6) pregnancy or lactation, (7) hormonal treatment including oral contraceptives, (8) current treatment of psychotropic, anti-inflammatory, steroids, or analgesic drugs.

HCCs were determined from 3 cm hair strands samples collected near the scalp from RP patients and healthy controls. In addition, RP patients were graded into severity disease groups, and their anxiety-stress status was analyzed by the State-Trait Anxiety Inventory (STAI) questionnaire.

2.2. Ophthalmological exam and degree of Retinitis Pigmentosa severity

Patients in this group were subjected to a complete ophthalmological examination (clinical ocular evaluation, best corrected visual acuity [BCVA], spectral domain optical coherence tomography [SD-OCT] and visual field test [VF]) and graded into severity disease groups according to Smith et al. (2013) (Smith et al., 2013).

For RP severity classification, clinical assessment and results from ancillary tests were used. Best BCVA in logarithm of the minimum angle of resolution (LogMAR) scale, mean deviation (MD) in automated perimetry (dB) and SD-OCT-measured outer retinal thickness (ORT) (distance from retinal pigmentary epithelium to inner-plexiform layer measured in micrometers- μm) at fovea were considered. The RP patients were graded from mild to severe on a 0–4 points scale (Smith et al., 2013). Clinical assessment included an evaluation of 4 of the distinguishing clinical signs in RP. The presence of significant lens opacity, moderate or severe optic disc atrophy, bone spicules or macular pathology (epiretinal membrane or cystoid macular oedema) scored 1 point each (O'Neal and Luther, 2021; Smith et al., 2013; Verbakel et al., 2018).

BCVA was recorded using the Early Treatment Diabetic Retinopathy Study (ETDRS) optotypes, with "Chart 2" in LogMAR measures, from "Precision Vision" (Woodstock, Illinois, USA) (Elliott and Flanagan, 2007). Chart testing distance was initially fixed in 4 m, for patients with enough VA. If patients could not see any of the characters, distance was reduced to 1 m. In cases 1 m distances was neither enough patient was asked to count fingers (CF: 2) in nearer distances, which were registered, asked for hand motion (HM: 3) or registered as light perception (LP) or absence of LP (NLP) in worst cases. VA until 0.20 LogMAR did not score, between 0.21 and 0.40 scored 1 point, 0.41–0.60 2 points, 0.61–0.80 scored 3 points and over 0.80 (including PL and NPL) scored the maximum, 4 points.

The Mean Deviation (MD) index of the visual field was gathered with a "Humphry Visual Field Analyzer" (HFA, Carl Zeiss Meditec, Dublin, CA). The automated perimeter was used to establish functional damage in both eyes, using the Swedish Interactive Threshold Algorithm (SITA)-Standard (SS) 24-2 strategy (Igarashi et al., 2016). Cut-off points in automated perimetry were established by MD (dB) in negative values: values until 15 dB did not score, between 15 and 20 1 point, 20.1–25 2 points, 25.1–30 3 points and values over 30 dB of MD scored the maximum, 4 points (Smith et al., 2013).

OCT scans were performed to establish objective structural damage (Liu et al., 2016). The chosen protocol to analyze central retinal damage was macular cube 200×200 and measures were taken using a Spectral Domain "Cirrus HD-OCT 5000" (Carl Zeiss Meditec, Calif., USA). Outer retinal thickness at fovea, measured in microns (μ), was considered for RP classification: retinal thickness over 160 μ did not score, 160.1–130 μ scored 1 point, 130.1–100 μ scored 2 points, 100.1–70 μ scored 3 points

and values under 70 μ scored the maximum 4 points (Smith et al., 2013).

As a result of the sum of clinical assessment and ancillary test scores, total severity grade (TSG) variable was calculated. It ranged from 0 to 16, considering punctuations between 0 and 3 a mild disease grade, 4–7 moderate and 8–16 severe. When total severity grade was established in our patients, most of them resulted in an advanced stage of disease and it was decided to stratify patients in only two groups mild-moderate named grade 2 and severe disease, grade 3 (Smith et al., 2013).

2.3. Anxiety status evaluation

The STAI questionnaire was used to characterize the anxiety trait by the participants. The questionnaire was completed twice (state-trait section at first and state section only at second visit as recommended). Those visits were separated for a week. The STAI questionnaire is a validated scale for grading anxiety either as an occasional event, a state, a sustained condition, or a trait (Novy et al., 1995; Rodrigo and Lusiardo, 1988; Spielberger et al., 1971). It is composed by 40 items that receive a specific score according to its frequency. The minimum score is 0 meaning no stress-anxiety perceived, meanwhile 60 is the upper limit. However, the results can be categorized in 4 groups: (1) not anxious (0–19), (2) mild grade (20–28), (3) high grade (29–39), (4) severe grade (>40) (Spielberger et al., 1971).

2.4. Chronic stress: hair sample collection and cortisol measurement

Relevant sociodemographic variables (age, smoking status, body mass index, employment status, physical exercise, or sex) and ocular and medical histories were recorded. Then we further analyzed hair strands from the participants.

Hair strands were taken near the scalp and from a posterior vertex location and kept in aluminium foil to protect them from light and humidity. Afterwards, the hair was washed twice using isopropanol and left them dry for 48 h at room temperature (RT). Then, 1 cm proximal hair and 1 cm distal hair were cut for analysis. The hair samples were cut into small pieces and weighed. The samples were into 500 μ l of methanol and left in agitation for 72 h at RT. Then, the samples were centrifuged (14,000 g) for 2 min at RT, the supernatant were separated, and the pellet discarded. The recovered supernatants were introduced into the Eppendorf™ Concentrator Plus (Eppendorf AG, Hamburg, Germany) for 2 h at RT. The final extract was reconstituted in 150 μ l of phosphate buffered saline 1% (PBS).

The Cortisol levels were determined using a specific Cortisol ELISA test following the manufacture instructions (DRG Salivary Cortisol ELISA, DRG Instruments GmbH, Marburg, Germany).

2.5. Statistical analysis

Data were presented as mean and standard deviation (SD) for quantitative variables and percentages for qualitative variables. The *t*-test was used to compare the differences between means from study groups. The mild RP group was only constituted by 2 patients. To facilitate the comparison of different data between groups, we combined both subgroups (mild and moderate) into a single group (mild-moderate). Chi-squared was used to analyze the association between categorical variables. HCC was logarithmically transformed since hormone values were not normally distributed (Supplementary Fig. 1). The general linear model was used to compare the differences in Log-transformed HCC mean values between groups including age, grade of severity, stress status, and sex as covariable, since hair cortisol levels tend to increase with age (Wester et al., 2017). Also, a post hoc sensitivity analysis was performed excluding outliers. The linear association between quantitative variables was measured by Pearson's correlation coefficient. The statistical significance was set at $p < 0.05$. Data was analyzed by IBM-SPSS Statistics software version 22.

3. Results

3.1. Baseline characteristics, stress status and anxiety status

Seventy-eight patients with RP (47 (60.3%) males) and 148 healthy controls (70 (47.29%) males) were included (Table 1). Patients with RP were 51.59 ± 13.40 years old, and the age of the participants in healthy group was 41.29 ± 5.14 years, being RP patients older than controls ($p = 0.001$).

At the time of evaluation, 52 (67%) of patients had a severe RP (33 (63.5%- males) and 19 (36.5%) females) with a mean age 53.83 ± 13.17 years old, and 26 (33%) a mild-moderate grade (14 (53.8%) males) and 12 (46.2%) females) with a mean age 47.12 ± 12.94 years old. Patients with a tougher severity degree of RP tended to be older ($p = 0.036$) which agrees with the literature due to chronic nature of disease". Mean age in mild-moderate group age was 47.1 ± 12.9 and 53.8 ± 13.1 in the severe group ($p = 0.036$).

The 23.1% of the RP patients ($n = 18$) showed high-anxiety status ("STAI-status 29–39"), 58 patients (74.35%) severe-anxiety status ("STAI-status >40"), and only 2.55% ($n = 2$) had normal score. Patients with severe and mild-moderate RP ($n = 38$ and 20, respectively) did not show significant differences when their perceived anxiety scores were compared.

3.2. Baseline clinical characteristics of RP patients

Clinical appearance data are summarized in Table 2. Mean visual acuity in LogMAR unit was 1.3 (range 0.22–NLP) in severe RP patients and 0.29 (range –0.08–1.12) in mild-moderate RP patients ($p < 0.001$).

Humphrey SITA fast 24–2 visual fields were recorded for 73 out of 78 patients. Perimetry could not be completed by 14 subjects with LP vision, who were unable to identify any stimuli. Mean MD in severe RP patients was -30.07 dB (range -33.44 to -22.52 dB) and -23.14 dB (range -31.31 to -5.0 dB) in mild-moderate RP patients ($p < 0.001$).

Table 1
Baseline characteristics of participants and anxiety status.

	RP patients n = 78	Controls n = 148	p-value
Age, yrs. (mean, SD)	51.59 ± 13.40	41.29 ± 5.14	0.001
Sex, male/female	47/31	70/78	0.070
Grading severity	severe 52 (67%) mild-moderate 26 (33%)	–	–
Anxiety status	not stress-anxiety (0–19) 2 (2.55%) mild grade (20–28) – high grade (29–39) 18 (23.1%) severe grade (>40) 58 (74.35%)	–	–
Duration of RP disease, yrs. (mean, range)	25.4 (2–50)	–	–
Log-HCC, Log ₁₀ pg/mg (mean, SD)	2.62 ± 0.14	1.99 ± 0.23	<0.001
Smoking or Drugs, No/Yes	76/2	110/38	<0.001
BMI (kg/m ²)	23.34 ± 2.94	–	–
Employment status	Student 3 Employed 15 Unemployed 42 Retired 18	2 89 8 3	0.3431 <0.001 <0.001 <0.001
Regular Physical exercise, No/Yes	56/22	67/47	0.097
Hair dyes, No/Yes	53/13	–	–

Data are presented as mean \pm SD, mean (range) or frequency distribution. RP: Retinitis Pigmentosa, yrs: years, HCC: Hair Cortisol Concentration, BMI: Body mass index.

Table 2
Baseline clinical characteristics of RP patients.

	Severe RP n = 52	Mild-moderate RP n = 26	p-value
Visual acuity (mean ± SD)	1.35 ± 0.46	0.29 ± 0.30	0.001
Clinical appearance			
Significant lens opacity	13	4	0.396
Optic disc atrophy	17	2	0.023
Bone spicules	45	13	0.001
Macular pathology	6	1	0.414
Perimetry dB (mean, range)	−30 (−33.4 to −22.5)	−23.1 (−31.3 to −5)	0.001
ORT at the fovea (mean ± SD)	150.7 ± 23.48	179.4 ± 17.18	0.001

Data are presented as mean (SD), mean (range) or frequency distribution. RP: Retinitis Pigmentosa, dB: decibel, ORT: outer retinal thickness.

OCT scans were done in 70 patients that revealed a mean full retinal thickness at the fovea of 223.87 μm (range 95.6–287.5 μm) and a mean ORT at the fovea of 150.7 μm (range 65.9–197.3 μm) in severe RP patients and 179.4 μm (range 87.5–246.5 μm) in mild-moderate RP patients ($p < 0.001$). OCT scans could not be performed in 8 subjects with LP vision and nystagmus. There was a good correlation between the clinical appearance (graded from mild to severe on a 0–4 points scale) and each of the quantitative measures of disease severity; BCVA (-0.54 , $p < 0.001$), MD (-0.63 , $p = 0.001$) and ORT (-0.70 , $p = 0.04$) (Supplementary Fig. 2).

3.3. Hair cortisol concentrations (HCC)

The collection of scalp hair succeeded in 70 patients. Since there was a significant age difference between the two groups (RP patients and controls) HCC study was adjusted by age. Before age adjustment, HCC results were 2.42 ± 0.12 in RP patients and 1.79 ± 0.21 in controls ($p < 0.001$); 2.91 ± 0.19 in severe RP patients and 2.23 ± 1.11 in mild-moderate ones ($p < 0.001$); and 2.74 ± 0.27 in severely stressed patients vs. 2.39 ± 0.21 in highly stressed ($p < 0.001$).

As mentioned, HCC was not normally distributed, thus logarithmic transformation was done in all values for statistical analyses. Mean \pm SD in HCC was $2.62 \pm 0.14 \text{ Log}_{10} \text{ pg/mg}$ in patients and $1.99 \pm 0.23 \text{ Log}_{10} \text{ pg/mg}$ in controls ($p < 0.001$) (Fig. 1A) and ranged from 2.56 to 2.68 $\text{Log}_{10} \text{ pg/mg}$ in RP patients and from 1.93 to 2.06 $\text{Log}_{10} \text{ pg/mg}$ in healthy controls. HCC was also higher in patients with an advanced stage of RP, $2.71 \pm 0.12 \text{ Log}_{10} \text{ pg/mg}$, than in patients with a mild-moderate grade $2.43 \pm 1.17 \text{ Log}_{10} \text{ pg/mg}$ ($p < 0.011$, Fig. 1B). Mean HCC in RP patients with severe stress-anxiety were $2.70 \pm 0.24 \text{ Log}_{10} \text{ pg/mg}$ and $2.49 \pm 0.19 \text{ Log}_{10} \text{ pg/mg}$ in mild-moderate RP group ($p = 0.001$) (Fig. 1C).

Likewise, mean HCC-log in male RP patients were $2.67 \pm 0.26 \text{ Log}_{10} \text{ pg/mg}$ and $2.58 \pm 0.21 \text{ Log}_{10} \text{ pg/mg}$ in female patients. Also, after correction for age, no significant differences in HCC between male and female RP patients were found ($p = 0.163$). Moreover, no linear association between age and HCC-log was found in our sample group of RP patients ($p = 0.401$; $r = 0.096$). No differences were found in life-style related confounders (smoking status, employment status, or physical exercise) between groups ($p > 0.05$).

4. Discussion

This study aimed to evaluate the relationship between chronic stress, anxiety and cortisol levels and revealed that HCC in patients with RP were significantly different when compared to healthy controls. In addition, differences in HCC were found in RP patients in relation to their different grades of severity and anxiety status. Hence, we suggest that HCC may be useful in monitoring anxiety and stress and could be a sensitive tool for identifying patients at risk of higher stress and thus, more risk of suffering fluctuations in their vision.

To the best of our knowledge, this is the first study evaluating HCC, anxiety status, and grade of disease severity in a cohort of RP patients.

Visual function fluctuations in RP patients have been previously investigated, focusing on one or multiple measures of their BCVA, VF, and/or electrophysiological tests, and how do they vary over time (Ava K Bittner et al., 2011; Holopigian et al., 1996). Within RP patients, vision tends to get worse as the disease progresses and RP severity is expected to be higher in older patients due to chronic nature of disease. Nonetheless, a high variability of vision in RP compared to other vision threatening diseases has been shown, with large differences in measures' rate of change (Ava K Bittner et al., 2011; Holopigian et al., 1996). Although the reason for these fluctuations has not been completely unveiled yet, perceived stress could be involved in its pathogenesis. Not only does the progressive loss of vision in RP contribute to anxiety, stress, and negative psychological states, but the uncertainty associated with day-to-day fluctuations in vision may also aggravate the situation and should not be discounted.

RP patients have commonly reported that stress makes their vision worse and even described stress-related episodes of acute visual loss (Heckenlively et al., 1988). Moreover, an increased frequency of unpleasant symptoms like photopsia, which appear to occur more frequently in advanced cases, has also been related to anxiety status in RP patients (Bittner et al., 2012). In addition, it has been reported that variations in vision are partially improved when the stress was alleviated (Ava K. Bittner et al., 2011).

The relevance for measuring stress and anxiety in RP patients lies in the hypothesis that they could be, at least in part, involved in the fluctuations in the visual function they suffer, based, mainly, on two considerations. Firstly, RP patients often report that their vision decline happened at a time of highly or prolonged mental stress (or shortly

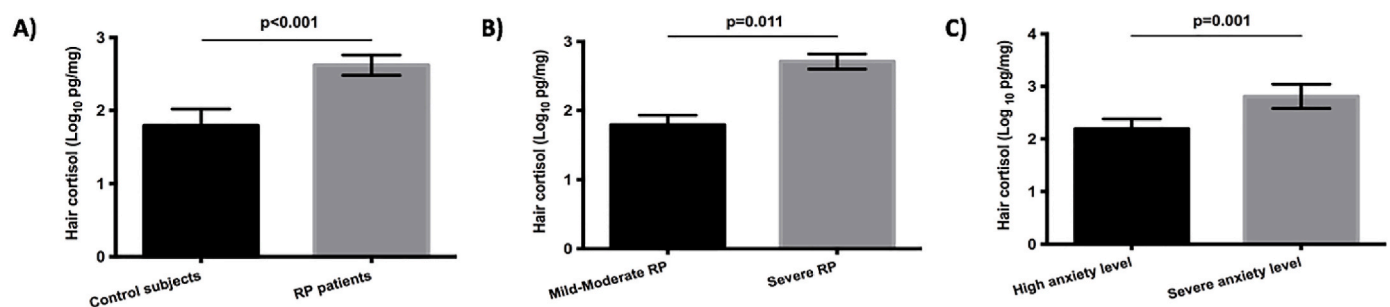


Fig. 1. Mean \pm SD Log-transformed HCC and differences between groups. A) HCC was significantly higher in RP patients $2.62 \pm 0.14 \text{ Log}_{10} \text{ pg/mg}$ than in controls $1.99 \pm 0.23 \text{ Log}_{10} \text{ pg/mg}$ ($p < 0.001$). B) RP patients with a severe grade of disease also had superior concentrations than mild-moderate grade (severe RP: $2.71 \pm 0.12 \text{ Log}_{10} \text{ pg/mg}$; mild-moderate RP: $2.43 \pm 1.17 \text{ Log}_{10} \text{ pg/mg}$; $p = 0.011$). C) There also existed statistical and clinical differences between anxiety levels, severe group obtained $2.70 \pm 0.24 \text{ Log}_{10} \text{ pg/mg}$ vs. $2.49 \pm 0.19 \text{ Log}_{10} \text{ pg/mg}$ from high anxiety group ($p = 0.001$).

thereafter). Indeed, psychosomatic stress has already been linked to other vision losing conditions e.g., glaucoma, age related macular degeneration (AMD) or myopia (Sabel et al., 2018). Moreover, previous research has suggested that increased negative psychosocial states may result in an inefficient attentional cognitive state, leading to a more effortful and reduced capacity to process and react to visual information, and therefore more vision test variability (Ava K. Bittner et al., 2011; Rowe et al., 2007). The increasing difficulty in daily live tasks associated to the disabling nature of RP and the lack of effective therapy can lead to a continuous psychological distress on patients throughout their life, many of whom are young when diagnosed, and match these difficulties (O'Neal and Luther, 2021; Verbakel et al., 2018). This is consistent with the results of our study since those patients with more severe disease obtained higher scores of anxiety and stress. Secondly, biological responses to stress consist of a sustained chain release of hormones such as cortisol over periods of months. Even though RP is an inherited retinal disorder linked to genetic mutations, it is possible that additional factors, such as stress or anxiety, may influence its manifestation (Weleber and Gregory-Evans, 2005; Yang et al., 2018). In this context, other systemic biomarkers of stress have been studied clinically and experimentally in RP patients such as serum oxidants and antioxidant molecules (Ishizu et al., 2019) and inflammatory markers (Murakami et al., 2018; Noailles et al., 2018; Okita et al., 2020). Accordingly, increased levels of stress hormone on a tissue level might lead to specific alterations in choroid and retina secondary to vascular autoregulation problems (such as reduction ocular blood flow-OBF), increased vascular contractility, inhibited angiogenesis, and increased platelet activation with widespread consequences on the biochemical and physiological level (Sabel et al., 2018). For example, under stress conditions and in cases of barrier defects, endothelin-1 (ET-1), as in other tissues, could access retinal and choroidal vessels leading to vasoconstriction and a certain reduction of OBF (Dallinger et al., 2000; Flammer et al., 2001, 2013; Konieczka et al., 2014; Strenn et al., 1998). Although in RP patients OBF is already reduced in the atrophic tissue, due to a decreased demand for supply and vascular remodelling (Cuenca et al., 2014; Jones et al., 2016), a sustained stress state could ameliorate the reduction of OBF contributing to retinal degeneration (Konieczka et al., 2012, 2016).

Although the exact pathomechanism underlying this association needs to be further investigated, these findings indicate that chronic biological stress, as measured by HCC, could be linked to visual fluctuations in RP patients. HCC is a non-invasive and painless technique that offers not only advantages for patients but also for researchers. Besides, hair samples make possible to study a desired period by analysing the matching portion from the hair sample without repeated visits for patients. Age and sex have been presented as cofounders in HCC analysis because of the differences between sex and the inconstant secretion of cortisol throughout lifetime (Stalder et al., 2012; Staufenbiel et al., 2013). In addition, it has been proposed that HCC could be influenced by certain life-style related cofounders (smoking status, body mass index, employment status, hair dyes or physical exercise) although bibliographic results are mixed and contradictory (Dettenborn et al., 2012; Stalder et al., 2012). Nevertheless, a post-hoc analysis was conducted to study whether they influenced our results or not and none of them had a positive influence. Oral contraceptives have also shown HCC alterations in some studies, to avoid this effect, their use was considered an exclusion criterion (Manenschijn et al., 2013; Stalder et al., 2012).

Limitations of this study included small sample size (prevalence of RP is low, it is a rare disease) and observational character, which does not allow drawing absolute conclusions on any causal relationship. Since our patient population consisted mainly of advanced RP patients, mild RP patients are underrepresented. Another limitation was that BMI and hair dyes data from the control group were missing, however, this had no effect on the interpretation of the results in the RP group. In addition, according to the literature, there is no agreement on whether the BMI is a predictor of a higher concentration of cortisol in hair or about the influence of hair dyes in HCC results (Abdulateef, 2021;

Kristensen et al., 2017). A general limitation in studies applying the HCC method is that people with insufficient hair length are excluded from the analysis. This limitation could have some impact on bald RP patients. RP is genetically heterogeneous, which lead to a large heterogeneity of phenotype, age of onset, progression, and severity of the disease. This brings out a limitation of our findings. Studies with greater number of patients are required.

It is important to notice that this study was carried out in collaboration with RECYL, an association for low vision patients. We consider that biomedical scientists working together to patient's associations is crucial for research success and the improvement of patient's life quality, especially in rare diseases as RP.

In conclusion, according to the results of this study, HCC as a clinical measure for long term cortisol exposure in patients with RP are elevated when compared to controls. In addition, differences were found between different RP disease grade and anxiety status. We can hypothesize that HCC seems to be a new promising tool to identify RP patients at risk of vision loss. Further research unravelling the role of stress axis and the levels of cortisol in the vision fluctuations and progression of RP disease is required.

Authors' contributions

All authors contributed to the study conception and design. Material preparation, data collection and analysis were performed by Milagros Mateos-Olivares, Kevin Puertas-Neyra, María Isabel Peralta-Ramírez, Raquel González-Pérez, Javier Martín-Vallejo, Carmen García-Vázquez, Eva María Sobas, Ricardo Usategui-Martín and Salvador Pastor-Idoate. The first draft of the manuscript was written by Milagros Mateos-Olivares, Ricardo Usategui-Martín and Salvador Pastor-Idoate and all authors commented on previous versions of the manuscript. All authors read and approved the final manuscript.

Funding

This study was supported by grants from Gerencia Regional de Salud de Castilla y León (GRS, 1932/A/19) and from the Ministry of Science and Innovation of the Spanish Government (PID2020-114585RA-I00).

Declaration of competing interest

None.

Acknowledgements

We thank patients from RECYL and healthy subjects for their participation in the study and ERN-EYE for their support.

Appendix A. Supplementary data

Supplementary data to this article can be found online at <https://doi.org/10.1016/j.exer.2022.109019>.

References

- Abdulateef, D.S., 2021. Scalp hair sweating as a predictor of hair cortisol level in human compared to obesity and other confounders. *Sci. Rep.* 11 (11), 1–9. <https://doi.org/10.1038/s41598-021-02223-0>, 2021.
- Adam, E.K., Hawkey, L.C., Kudielka, B.M., Cacioppo, J.T., 2006. Day-to-day dynamics of experience-cortisol associations in a population-based sample of older adults. *Proc. Natl. Acad. Sci. U.S.A.* 103, 17058–17063. <https://doi.org/10.1073/pnas.0605053103>.
- Bittner, A.K., Edwards, L., George, M., 2010. Coping strategies to manage stress related to vision loss and fluctuations in retinitis pigmentosa. *Optometry* 81, 461–468. <https://doi.org/10.1016/j.optm.2010.03.006>.
- Bittner, A.K., Haythornthwaite, J.A., Diener-West, M., Dagnelie, G., 2012. Photopsias are related in part to perceived stress and positive mood in retinitis pigmentosa. *Eye* 26, 101–108. <https://doi.org/10.1038/eye.2011.247>.

- Bittner, Ava K., Ibrahim, M.A., Haythornthwaite, J.A., Diener-West, M., Dagnelie, G., 2011. Vision test variability in retinitis pigmentosa and psychosocial factors. official publication of the American Academy of Optometry Optom. Vis. Sci. 88, 1496. <https://doi.org/10.1097/OPX.0B013E3182348D0B>.
- Bittner, Ava K., Iftikhar, M.H., Dagnelie, G., 2011. Test-retest, within-visit variability of goldmann visual fields in retinitis pigmentosa. Investig. Ophthalmol. Vis. Sci. 52, 8042–8046. <https://doi.org/10.1167/iov.11-8321>.
- Cuenca, N., Fernández-Sánchez, L., Campello, L., Maneu, V., de la Villa, P., Lax, P., Pinilla, I., 2014. Cellular responses following retinal injuries and therapeutic approaches for neurodegenerative diseases. Prog. Retin. Eye Res. 43, 17–75. <https://doi.org/10.1016/j.preteyeres.2014.07.001>.
- Dallinger, S., Dorner, G.T., Wenzel, R., Graselli, U., Findl, O., Eichler, H.-G., Wolz, M., Schmetterer, L., 2000. Endothelin-1 contributes to hyperoxia-induced vasoconstriction in the human retina. Investig. Ophthalmol. Vis. Sci. 41, 864–869.
- Davenport, M.D., Tiefenbacher, S., Lutz, C.K., Novak, M.A., Meyer, J.S., 2006. Analysis of endogenous cortisol concentrations in the hair of rhesus macaques. Gen. Comp. Endocrinol. 147, 255–261. <https://doi.org/10.1016/j.ygcen.2006.01.005>.
- Dettenborn, L., Tietze, A., Kirschbaum, C., Stalder, T., 2012. The assessment of cortisol in human hair: associations with sociodemographic variables and potential confounders. Stress 15, 578–588. <https://doi.org/10.3109/10253890.2012.654479>.
- Elliott, D.B., Flanagan, J., 2007. Assessment of visual function. In: Clinical Procedures in Primary Eye Care. Butterworth-Heinemann, pp. 29–81. <https://doi.org/10.1016/B978-0-7506-8896-3.50007-9>.
- Flammer, J., Konieczka, K., Flammer, A.J., 2013. The primary vascular dysregulation syndrome: implications for eye diseases. EPMA J. 4 (1 4), 1–33. <https://doi.org/10.1186/1878-5085-4-14>, 2013.
- Flammer, J., Pache, M., Resnik, T., 2001. Vasospasm, its role in the pathogenesis of diseases with particular reference to the eye. Prog. Retin. Eye Res. 20, 319–349. [https://doi.org/10.1016/S1350-9462\(00\)00028-8](https://doi.org/10.1016/S1350-9462(00)00028-8).
- Galan, A., Chizzolini, M., Milan, E., Sebastiani, A., Costagliola, C., Parmeggiani, F., 2011. Good epidemiologic practice in retinitis pigmentosa: from phenotyping to biobanking. Curr. Genom. 12, 260–266. <https://doi.org/10.2174/138920211795860071>.
- García-León, M.A., Peralta-Ramírez, M.I., Arco-García, L., Romero-González, B., Caparros-González, R.A., Saez-Sanz, N., Santos-Ruiz, A.M., Montero-Lopez, E., González, A., González-Pérez, A.R., 2019. Correction: hair cortisol concentrations in a Spanish sample of healthy adults. PLoS One. <https://doi.org/10.1371/journal.pone.0221883>.
- Gibson, E.L., Checkley, S., Papadopoulos, A., Poon, L., Daley, S., Wardle, J., 1999. Increased salivary cortisol reliably induced by a protein-rich midday meal. Psychosom. Med. 61, 214–224. <https://doi.org/10.1097/00006842-199903000-00014>.
- Gow, R., Thomson, S., Rieder, M., van Uum, S., Koren, G., 2010. An assessment of cortisol analysis in hair and its clinical applications. Forensic Sci. Int. 196, 32–37. <https://doi.org/10.1016/j.forsciint.2009.12.040>.
- Hamel, C., 2006. Retinitis pigmentosa. Orphanet J. Rare Dis. 1, 1–12. <https://doi.org/10.1186/1750-1172-1-40>.
- Hartong, D., Berson, E., Dryja, T., 2006. Retinitis pigmentosa Prevalence and inheritance patterns. Lancet 368, 1795–1809.
- Heckenlively, J.R., Yoser, S.L., Friedman, L.H., Oversier, J.J., 1988. Clinical findings and common symptoms in retinitis pigmentosa. Am. J. Ophthalmol. 105, 504–511. [https://doi.org/10.1016/0002-9394\(88\)90242-5](https://doi.org/10.1016/0002-9394(88)90242-5).
- Hologipian, K., Greenstein, V., Seiple, W., Carr, R.E., 1996. Rates of change differ among measures of visual function in patients with retinitis pigmentosa. Ophthalmology 103, 398–405. [https://doi.org/10.1016/S0161-6420\(96\)30679-9](https://doi.org/10.1016/S0161-6420(96)30679-9).
- Igarashi, N., Matsuura, M., Hashimoto, Y., Hirasawa, K., Murata, H., Inoue, T., Ryo, O., Aihara, M., Asaoka, R., 2016. Assessing visual fields in patients with retinitis pigmentosa using a novel microperimeter with eye tracking: the MP-3. PLoS One 11. <https://doi.org/10.1371/journal.pone.0166666>.
- Ishizu, M., Murakami, Y., Fujiwara, K., Funatsu, J., Shimokawa, S., Nakatake, S., Tachibana, T., Hisatomi, T., Koyanagi, Y., Akiyama, M., Momozawa, Y., Ishibashi, T., Sonoda, K.H., Ikeda, Y., 2019. Relationships between serum antioxidant and oxidant statuses and visual function in retinitis pigmentosa. Investig. Ophthalmol. Vis. Sci. 60, 4462–4468. <https://doi.org/10.1167/IOVS.19-26927>.
- Jones, B.W., Pfeiffer, R.L., Ferrell, W.D., Watt, C.B., Marmor, M., Marc, R.E., 2016. Retinal remodeling in human retinitis pigmentosa. Exp. Eye Res. 150, 149–165. <https://doi.org/10.1016/j.exer.2016.03.018>.
- Karlén, J., Ludvigsson, J., Frostell, A., Theodorsson, E., Faresjö, T., 2011. Cortisol in hair measured in young adults - a biomarker of major life stressors? BMC Clin. Pathol. 11. <https://doi.org/10.1186/1472-6890-11-12>.
- King, S.L., Hegadoren, K.M., 2002. Stress hormones: how do they measure up? Biol. Res. Nurs. 4, 92–103. <https://doi.org/10.1177/1099800402238334>.
- Kiser, A.K., Dagnelie, G., 2008. Reported effects of non-traditional treatments and complementary and alternative medicine by retinitis pigmentosa patients. Clin. Exp. Optom. 91, 166–176. <https://doi.org/10.1111/j.1444-0938.2007.00224.x>.
- Konieczka, K., Flammer, A.J., Todorova, M., Meyer, P., Flammer, J., 2012. Retinitis pigmentosa and ocular blood flow. EPMA J. 3. <https://doi.org/10.1186/1878-5085-3-17>.
- Konieczka, K., Koch, S., Schoetzau, A., Todorova, M.G., 2016. Increased prevalence of flammer syndrome in patients with retinitis pigmentosa. Klinische Monatsblätter für Augenheilkunde 233, 448–452. <https://doi.org/10.1055/s-0041-111802>.
- Konieczka, K., Ritch, R., Traverso, C.E., Kim, D.M., Kook, M.S., Gallino, A., Golubnitschaja, O., Erb, C., Reitsamer, H.A., Kida, T., Kuryshva, N., Yao, K., 2014. Flammer syndrome. EPMA J. <https://doi.org/10.1186/1878-5085-5-11>.
- Kristensen, S.K., Larsen, S.C., Olsen, N.J., Fahrenkrug, J., Heitmann, B.L., 2017. Hair dyeing, hair washing and hair cortisol concentrations among women from the healthy start study. Psychoneuroendocrinology 77, 182–185. <https://doi.org/10.1016/j.psyneuen.2016.12.016>.
- Lenk, J., Sandner, D., Schindler, L., Pillunat, L.E., Matthé, E., 2019. Hair cortisol concentration in patients with active central serous chorioretinopathy is elevated – a pilot study. Acta Ophthalmol. 97, e568–e571. <https://doi.org/10.1111/aos.13979>.
- Lenk, J., Spoerl, E., Stalder, T., Schmiedgen, S., Herber, R., Pillunat, L.E., Raikup, F., 2017. Increased hair cortisol concentrations in patients with progressive keratoconus. J. Refract. Surg. 33, 383–388. <https://doi.org/10.3928/1081597X-20170413-01>.
- Liu, G., Liu, X., Li, H., Du, Q., Wang, F., 2016. Optical coherence tomographic analysis of retina in retinitis pigmentosa patients. Ophthalmic Res. <https://doi.org/10.1159/000445063>.
- Manenshijn, L., Schaap, L., van Schoor, N.M., van der Pas, S., Peeters, G.M.E.E., Lips, P., Koper, J.W., van Rossum, E.F.C., 2013. High long-term cortisol levels, measured in scalp hair, are associated with a history of cardiovascular disease. J. Clin. Endocrinol. Metabol. 98, 2078–2083. <https://doi.org/10.1210/jc.2012-3663>.
- Mifsud, K.R., Reul, J.M.H.M., 2018. Mineralocorticoid and glucocorticoid receptor-mediated control of genomic responses to stress in the brain. Stress. <https://doi.org/10.1080/10253890.2018.1456526>.
- Murakami, Y., Ikeda, Y., Nakatake, S., Fujiwara, K., Tachibana, T., Yoshida, N., Notomi, S., Hisatomi, T., Yoshida, S., Ishibashi, T., Sonoda, K.H., 2018. C-Reactive protein and progression of vision loss in retinitis pigmentosa. Acta Ophthalmol. 96, e174–e179. <https://doi.org/10.1111/AOS.13502>.
- Noailles, A., Maneu, V., Campello, L., Lax, P., Cuenca, N., 2018. Systemic inflammation induced by lipopolysaccharide aggravates inherited retinal dystrophy. Cell Death Dis. 9. <https://doi.org/10.1038/s41419-018-0355-X>.
- Novy, D.M., Nelson, D.v., Smith, K.G., Rogers, P.A., Rowzee, R.D., 1995. Psychometric comparability of the English-and Spanish-language versions of the state-trait anxiety inventory. Hisp. J. Behav. Sci. 17, 209–224. <https://doi.org/10.1177/07399863950172005>.
- Okita, A., Murakami, Y., Shimokawa, S., Funatsu, J., Fujiwara, K., Nakatake, S., Koyanagi, Y., Akiyama, M., Takeda, A., Hisatomi, T., Ikeda, Y., Sonoda, K.H., 2020. Changes of serum inflammatory molecules and their relationships with visual function in retinitis pigmentosa. Investig. Ophthalmol. Vis. Sci. 61. <https://doi.org/10.1167/IOVS.61.11.30>.
- O’Neal, T.B., Luther, E.E., 2021. Retinitis Pigmentosa, StatPearls. StatPearls Publishing.
- Otsuka, Y., Oishi, A., Miyata, M., Oishi, M., Hasegawa, T., Numa, S., Ikeda, H.O., Tsujikawa, A., 2020. Wavelength of light and photophobia in inherited retinal dystrophy. Sci. Rep. 10, 1–6. <https://doi.org/10.1038/s41598-020-71707-2>.
- Parmeggiani, F., Sorrentino, F.S., Ponzin, D., Barbaro, V., Ferrari, S., di Iorio, E., 2011. Retinitis pigmentosa: genes and disease mechanisms. Curr. Genom. 12, 238–249. <https://doi.org/10.2174/138920211795860107>.
- Prem Senthil, M., Khadka, J., Pesudovs, K., 2017. Seeing through their eyes: lived experiences of people with retinitis pigmentosa. Eye 31, 741–748. <https://doi.org/10.1038/eye.2016.315>.
- Rodrigo, G., Lusiardo, M., 1988. Note on the reliability and concurrent validity of the Spanish version of the State-Trait Anxiety Inventory. Percept. Mot. Skills 67, 926. <https://doi.org/10.2466/pms.1988.67.3.926>.
- Rowe, G., Hirsh, J.B., Anderson, A.K., 2007. Positive affect increases the breadth of attentional selection. Proc. Natl. Acad. Sci. U.S.A. 104, 383–388. <https://doi.org/10.1073/PNAS.0605198104>.
- Russell, E., Koren, G., Rieder, M., van Uum, S., 2012. Hair cortisol as a biological marker of chronic stress: current status, future directions and unanswered questions. Psychoneuroendocrinology. <https://doi.org/10.1016/j.psyneuen.2011.09.009>.
- Sabel, B.A., Wang, J., Cárdenas-Morales, L., Faiq, M., Heim, C., 2018. Mental stress as consequence and cause of vision loss: the dawn of psychosomatic ophthalmology for preventive and personalized medicine. EPMA J. <https://doi.org/10.1007/s13167-018-0136-8>.
- Smith, H.B., Chandra, A., Zambarkji, H., 2013. Grading severity in retinitis pigmentosa using clinical assessment, visual acuity, perimetry and optical coherence tomography. Int. Ophthalmol. 33, 237–244. <https://doi.org/10.1007/s10792-012-9678-2>.
- Spielberger, C.D., Gonzalez-Reigosa, F., Martínez-Urrutia, A., Natalicio, L.F., Natalicio, D.S., 1971. The state-trait anxiety inventory. Interam. J. Psychol. 5, 3–4.
- Stalder, T., Steudte, S., Miller, R., Skoluda, N., Dettenborn, L., Kirschbaum, C., 2012. Intraindividual stability of hair cortisol concentrations. Psychoneuroendocrinology 37, 602–610. <https://doi.org/10.1016/j.psyneuen.2011.08.007>.
- Staufenbiel, S.M., Penninx, B.W.J.H., Spijker, A.T., Elzinga, B.M., van Rossum, E.F.C., 2013. Hair cortisol, stress exposure, and mental health in humans: a systematic review. Psychoneuroendocrinology. <https://doi.org/10.1016/j.psyneuen.2012.11.015>.
- Strenn, K., Matulla, B., Wolz, M., Findl, O., Bekes, M.C., Lamsfuss, U., Graselli, U., Rainer, G., Menapace, R., Eichler, H.G., Schmetterer, L., 1998. Reversal of endothelin-1-induced ocular hemodynamic effects by low-dose nifedipine in humans. Clin. Pharmacol. Therapeut. 63, 54–63. [https://doi.org/10.1016/S0009-9236\(98\)90121-7](https://doi.org/10.1016/S0009-9236(98)90121-7).
- van Haalen, F.M., van Dijk, E.H.C., Savas, M., Brinks, J., Dekkers, O.M., Dijkman, G., van Rossum, E.F.C., Biermasz, N.R., Boon, C.J.F., Pereira, A.M., 2020. Hair cortisol concentrations in chronic central serous chorioretinopathy. Acta Ophthalmol. 98, 390–395. <https://doi.org/10.1111/aos.14269>.
- Verbakel, S.K., van Huet, R.A.C., Boon, C.J.F., den Hollander, A.I., Collin, R.W.J., Klaver, C.C.W., Hoyng, C.B., Roepman, R., Klevering, B.J., 2018. Non-syndromic retinitis pigmentosa. Prog. Retin. Eye Res. 66, 157–186. <https://doi.org/10.1016/j.preteyeres.2018.03.005>.

- Weleber, R.G., Gregory-Evans, K., 2005. Retinitis pigmentosa and allied disorders. In: *Retina*, fourth ed. Elsevier Inc. <https://doi.org/10.1016/B978-0-323-02598-0.50023-9> 395–498.
- Wennig, R., 2000. Potential problems with the interpretation of hair analysis results. In: *Forensic Science International*. *Forensic Sci Int*, pp. 5–12. [https://doi.org/10.1016/S0379-0738\(99\)00146-2](https://doi.org/10.1016/S0379-0738(99)00146-2).
- Wester, V.L., Noppe, G., Savas, M., van den Akker, E.L.T., de Rijke, Y.B., van Rossum, E.F. C., 2017. Hair analysis reveals subtle HPA axis suppression associated with use of local corticosteroids: the Lifelines cohort study. *Psychoneuroendocrinology* 80, 1–6. <https://doi.org/10.1016/j.psyneuen.2017.02.024>.
- Wolfram, M., Bellingrath, S., Feuerhahn, N., Kudielka, B.M., 2013. Cortisol responses to naturalistic and laboratory stress in student teachers: comparison with a non-stress control day. *Stress Health* 29, 143–149. <https://doi.org/10.1002/smi.2439>.
- Yang, Y.J., Peng, J., Ying, D., Peng, Q.H., 2018. A brief review on the pathological role of decreased blood flow affected in retinitis pigmentosa. *J. Ophthalmol.* <https://doi.org/10.1155/2018/3249064>.