


RESEARCH ARTICLE

Comparative anatomy of the ligaments and muscles of the radiocarpal joint in chimpanzees and humans

Josep Maria Potau^{1,2}  | Juan Francisco Pastor³ | Félix Jesús de Paz³ | Mercedes Barbosa³ | Mónica Gómez¹ | Marina de Diego¹ | Aroa Casado^{1,2}

¹Unit of Human Anatomy and Embryology, University of Barcelona, Barcelona, Spain

²Institut d'Arqueologia de la Universitat de Barcelona (IAUB), Faculty of Geography and History, University of Barcelona (UB), Barcelona, Spain

³Department of Anatomy and Radiology, University of Valladolid, Valladolid, Spain

Correspondence

Josep Maria Potau, Unit of Human Anatomy and Embryology, University of Barcelona, C/Casanova 143, 08036 Barcelona, Spain. Email: jpotaub@ub.edu

Funding information

European Union (FEDER), Grant/Award Number: CGL2014-52611-C2-2-P; Ministerio de Economía y Competitividad de España; Universitat de Barcelona, Grant/Award Number: APIF-UB 2016/2017

Abstract

Objectives: In the present study, we have analyzed the anatomy of the radiocarpal joint ligaments and muscles in *Pan troglodytes* and *Homo sapiens* in order to identify similarities and differences between the two species that may be related to differences in hand use and function.

Materials and Methods: Anatomical dissections of the ligaments and muscles of the radiocarpal joint were performed in six adult chimpanzees and 12 humans. The mass of each ligament and of the functional ligament groups were calculated relative to the total ligament mass and compared between the two species. The mass of the functional muscle groups relative to the total mass of the muscles of the radiocarpal joint was also calculated and compared between the two species.

Results: The ligaments of the radiocarpal joint had similar anatomical characteristics in chimpanzees and humans. The relative mass of the palmar ligaments was greater in humans, while that of the dorsal radiocarpal ligament was greater in chimpanzees. In both species, the relative mass of the palmar and dorsal muscle groups was inversely related to that of the corresponding ligament groups.

Discussion: The greater relative mass of the palmar ligaments in humans may be related to the importance of wrist extension during manipulative tasks. The greater relative mass of the dorsal radiocarpal ligament in chimpanzees may be related to the need to stabilize the radiocarpal joint in flexion, mainly during arboreal locomotion.

KEYWORDS

chimpanzee, radiocarpal joint, wrist ligaments

1 | INTRODUCTION

Relatively few studies have reported qualitative or quantitative data on soft tissues in hominoid primates, mainly due to the difficulty in conducting detailed anatomical studies in this group of primates. Nonetheless, it is important to increase our knowledge of the anatomical characteristics of hominoid primates, which are closely related phylogenetically to *Homo sapiens* (Almécija et al., 2021). The superfamily Hominoidea (hominoid primates) includes the family Hylobatidae (gibbons and siamangs) and the family Hominidae (great

apes and humans). The family Hominidae includes the subfamilies Ponginae (orangutans) and Homininae (gorillas, chimpanzees, bonobos, and humans) (Almécija et al., 2021). In fact, chimpanzees and bonobos are the hominine primates most closely related to humans (Prüfer et al., 2012), so their study will allow a better understanding of certain morphological and functional details of modern humans. Comparative studies of the musculoskeletal system of primates have mostly focused on osteological and muscular analyses (e.g. Carlson, 2006; Marzke et al., 1999; Michilsens et al., 2009; Myatt et al., 2012; Oishi et al., 2009; Potau et al., 2009; Thorpe et al., 1999; Tuttle et al., 1972;

This is an open access article under the terms of the [Creative Commons Attribution-NonCommercial-NoDerivs](https://creativecommons.org/licenses/by-nc-nd/4.0/) License, which permits use and distribution in any medium, provided the original work is properly cited, the use is non-commercial and no modifications or adaptations are made.

© 2022 The Authors. *American Journal of Biological Anthropology* published by Wiley Periodicals LLC.

Van Leeuwen et al., 2018), while ligaments, especially those of the upper limbs, have received relatively little attention (Sarmiento, 1988; Shrewsbury, 2003; Tuttle, 1969; Van Leeuwen et al., 2019), in spite of the fact that they are basic structures directly involved in the physiology of joints (Nordin & Frankel, 2001; Taleisnik, 1985).

The main functions of ligaments are to stabilize joints, restrict their movements, maintain correct contact between joint surfaces, and transmit loads generated during the use of the joint (Berger, 1997; Nordin & Frankel, 2001). Also, ligaments contain mechanoreceptors that capture mechanical stimuli that act on the joint and influence periarticular muscles through ligament-muscular reflexes (Apergis, 2013). These reflexes have been described in various joints in humans, including the wrist (Hagert et al., 2009). This functional importance of ligaments suggests that by studying them, we can better understand the anatomical and functional characteristics of the large joint complexes of primates. This is especially evident in those joints subjected to high functional loads during use, such as the wrist of the chimpanzees (Orr, 2017), which must combine the mobility required for the handling of objects (Hopkins et al., 2002) with the stability necessary to withstand the compressive forces of knuckle-walking (Pontzer et al., 2014; Thompson et al., 2018) and the tensile forces of suspensory behavior like vertical climbing or clambering (Hunt, 1991; Whitehead, 1993). Despite their functional importance, little is known about the anatomical characteristics of the ligaments of the radiocarpal joint in chimpanzees. Most studies have focused on the thickening of the palmar joint capsule (Tuttle, 1969) or of the palmar ulnocarpal (PUC) ligament (Sarmiento, 1988), which increase wrist stability in chimpanzees as an adaptation to knuckle-walking.

In humans, in contrast, the anatomical and functional characteristics of the ligaments of the radiocarpal joint are well known (Apergis, 2013; Cardoso & Szabo, 2007; Taljanovic et al., 2011). The palmar region of the joint capsule is reinforced by the palmar radiocarpal (PRC) ligament and by the PUC ligament (Apergis, 2013; Ringler & Murthy, 2015) (Figure 1). The PRC ligament comprises the radioscapophcapitate (RSC)

ligament, which connects the palmar surface of the styloid process of the radius to the scaphoid and capitate (Buijze et al., 2011); the long radiolunate (LRL) ligament, which connects the palmar surface of the radial scaphoid fossa with the lunate; and the short radiolunate (SRL) ligament, which connects the palmar surface of the radial lunate fossa with the lunate bone (Ringler & Murthy, 2015). The PUC ligament comprises the ulnolunate, ulnotriquetral and ulnocapitate ligaments (Taljanovic et al., 2011). These three ligaments originate in the palmar radioulnar ligament and in the fovea of the ulnar head and insert into the lunate, triquetrum and capitate, respectively. The RSC, LRL and SRL ligaments together form the main stabilizing element of the radiocarpal joint in humans (Apergis, 2013). These ligaments restrict the dorsal translation of the carpus and tighten during wrist extension. Also, the RSC stabilizes the scaphoid, while the LRL and SRL stabilize the lunate (Apergis, 2013; Ringler & Murthy, 2015). The PUC ligament, which also stabilizes the radiocarpal joint during wrist extension (Apergis, 2013), is part of the triangular fibrocartilage complex (TFCC), which separates the distal radioulnar joint from the proximal carpal bones in hominoid primates (Palmer & Werner, 1981), contributing to the stability of the distal radioulnar joint (Apergis, 2013).

The dorsal region of the radiocarpal joint capsule is reinforced by the dorsal radiocarpal (DRC) ligament (Apergis, 2013; Rainbow et al., 2012) (Figure 2). This ligament originates at the dorsal edge of the distal radial epiphysis, distally and ulnarly to the dorsal tubercle, and inserts into the dorsal surface of the lunate and triquetrum (Apergis, 2013). The DRC ligament tightens during flexion and wrist radial deviation (Rainbow et al., 2012), restricting these movements and helping to stabilize the lunate (Rainbow et al., 2012; Ringler & Murthy, 2015). The radial region of the radiocarpal joint capsule is reinforced by the radial collateral (RC) ligament (Figures 1 and 2), which extends between the radial styloid process and the scaphoid (Orlandi et al., 2012; Ringler, 2013) and which tightens during wrist ulnar deviation. Some authors consider the RC ligament to be a part

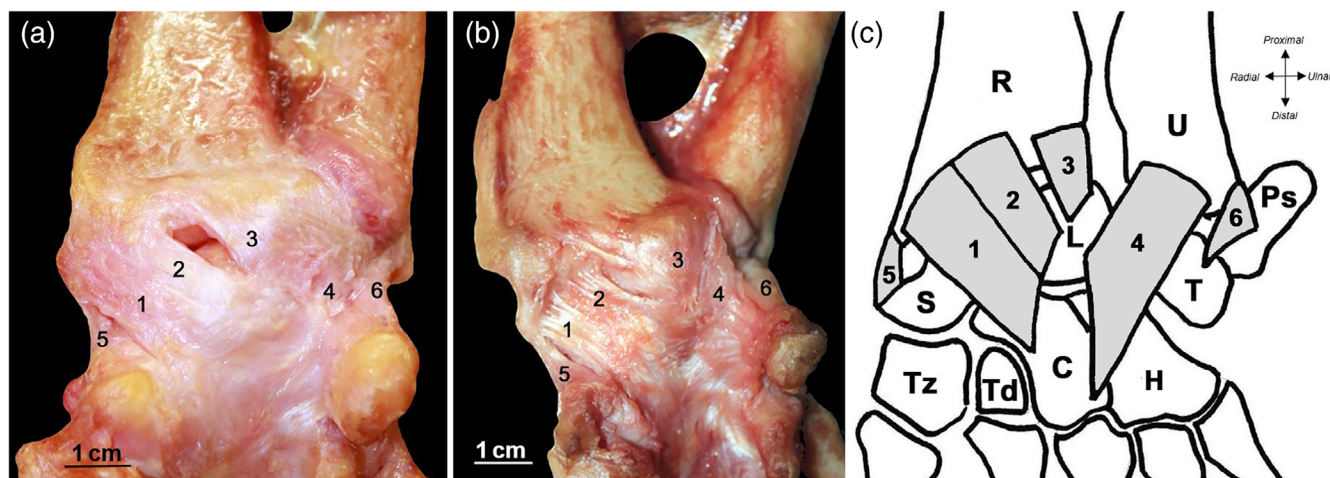


FIGURE 1 Palmar view of the wrist ligaments in (a) *Homo sapiens* (right hand, specimen HS02) and (b) *pan troglodytes* (right hand, specimen PT04). (c) Anatomical drawing of the chimpanzee wrist. 1 = Radioscapophcapitate (RSC) ligament; 2 = long radiolunate (LRL) ligament; 3 = short radiolunate (SRL) ligament; 4 = palmar ulnocarpal (PUC) ligament; 5 = radial collateral (RC) ligament; 6 = ulnar collateral (UC) ligament; R = radius; U = ulna; S = scaphoid; L = lunate; T = triquetrum; Ps = pisiform; Tz = trapezium; td = trapezoid; C = capitate; H = hamate

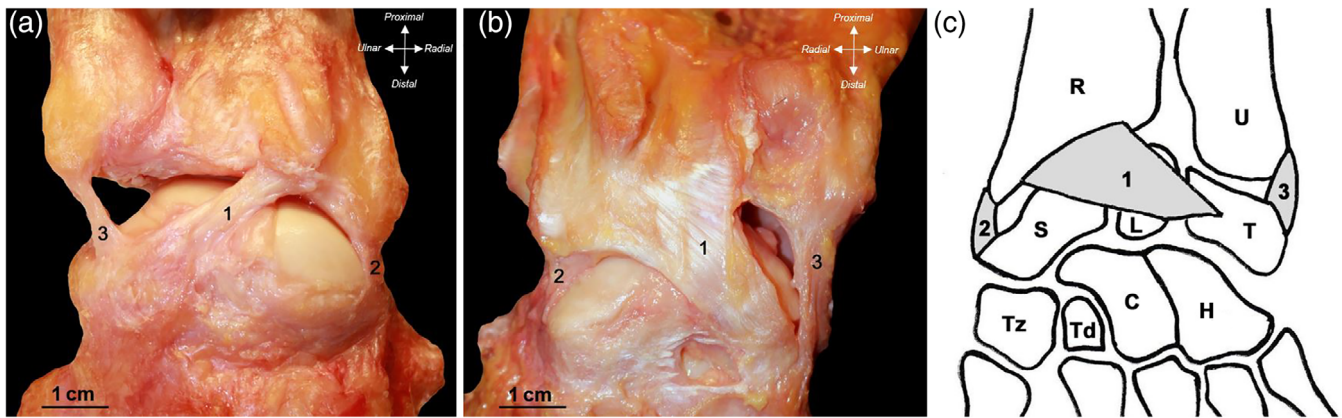


FIGURE 2 Dorsal view of the wrist ligaments in (a) *Homo sapiens* (right hand, specimen HS02) and (b) *pan troglodytes* (left hand, specimen PT01). (c) Anatomical drawing of the chimpanzee wrist. 1 = dorsal radiocarpal (DRC) ligament; 2 = radial collateral (RC) ligament; 3 = ulnar collateral (UC) ligament; R = radius; U = ulna; S = scaphoid; L = lunate; T = triquetrum; Tz = trapezium; Td = trapezoid; C = capitate; H = hamate

of the RSC ligament and not a differentiated ligament (Apergis, 2013; Ringler & Murthy, 2015). Finally, the ulnar region of the radiocarpal joint capsule is reinforced by the ulnar collateral (UC) ligament (Figures 1 and 2), which extends between the ulnar styloid process, the pisiform and the triquetrum. Some authors believe that the UC ligament should be considered a thickening of the joint capsule of the TFCC and not a differentiated ligament (Brown et al., 1998; Orlandi et al., 2012).

In the present study, we have performed a qualitative and quantitative anatomical study of the ligaments of the radiocarpal joint in chimpanzees and compared these with the ligaments in humans. We chose to focus on chimpanzees due to their close phylogenetic relationship with humans (Prüfer et al., 2012) and to the specific morphological and functional characteristics of the hand in chimpanzees. Chimpanzees and bonobos have a well-muscled hand in the palmar region (Van Leeuwen et al., 2018; Zihlman & Underwood, 2019). This large mass makes their hands strong—an anatomical adaptation to arboreal locomotion—while at the same time keeping them flexible enough for a variety of tasks. The multifunctional hand of chimpanzees can be used to grab food and other objects (Marzke et al., 2015), to manipulate vegetation to build nests, to use objects like tools (Hernandez-Aguilar et al., 2007), and to communicate (Goodall, 1986). At the same time, the hands of chimpanzees have a relatively long carpus and relatively short phalanges—an anatomical adaptation to knuckle-walking (Drapeau & Ward, 2007). In our quantitative analysis, we compared the relative mass of the wrist ligaments in chimpanzees and humans. The principal cells in ligaments, the fibroblasts, increase the expression of type I collagen, which is the main component of the extracellular matrix of ligaments, when they are under mechanical strain (Breen, 2000). Ligaments under greater strain will have a larger amount of type I collagen, and thus a greater mass, as has been observed in animals undergoing physical exercise, which have stronger and more rigid ligaments as well as collagen fibers with longer diameters (Tipton et al., 1970).

Since ligaments stabilize joints and transmit the functional loads generated during their use (Nordin & Frankel, 2001), we hypothesized that there would be significant differences between humans and chimpanzees in the different groups of ligaments of the radiocarpal

joint and that these differences would be related to the different use of the hand in the two species. Specifically, these differences would be related to the greater compressive and tensile forces acting on the wrist of chimpanzees due to their knuckle-walking and suspensory locomotion (Richmond & Strait, 2000; Kelly, 2001; Richmond et al., 2001), compared to modern humans, who use the wrist and hand mainly in manipulative tasks (Gebo, 2014). In chimpanzees, the wrist is flexed during suspensory locomotion and vertical climbing (Sarmiento, 1988). On the other hand, the wrist is slightly in extension and has an ulnar deviation during the stance phase of knuckle-walking (Kivell & Schmitt, 2009; Thompson, 2020). This leads us to hypothesize that chimpanzees would have a larger relative mass of the dorsal and radial ligaments, which are subject to greater mechanical strain at these times. In humans, in contrast, the functional position of the hand is associated with an extension of the wrist to allow the maximum amount of manual force (Hazelton et al., 1975; Volz et al., 1980), leading us to expect a larger relative mass of the palmar ligaments.

The main objective of our study is to amplify the scant information currently available on the anatomy of the wrist ligaments of chimpanzees, which will allow us to better understand the functional aspects of this important anatomical region in a species closely related to humans. In addition, since some of these ligaments leave clearly identifiable marks on the distal radial epiphysis (Casado et al., 2019), this increased knowledge will help improve the interpretation of these bone impressions in fossil primates. This, in turn, will facilitate the assignment of a particular locomotor behavior to fossil primates with a well-preserved distal radial epiphysis.

2 | MATERIALS AND METHODS

2.1 | Muscle and ligament samples and dissection

Six upper limbs of chimpanzees and 12 of humans were dissected for this study (Table 1). The upper limbs of chimpanzees were dissected

TABLE 1 Percentages of the masses of the individual ligaments of the radiocarpal joint relative to the total mass of the ligaments

Sample	ID	Age (years)	Sex	Body weight	Cause of death	%RSC	%LRL	%SRL	%PUC	%DRC	%RC	%UC
HS01	29B	83	M	NA	NA	14.0	9.8	13.8	21.6	23.3	6.7	10.7
HS02	73B	88	M	NA	NA	15.9	15.9	13.8	27.2	12.6	5.4	9.2
HS03	91B	81	M	NA	NA	19.5	15.2	7.2	12.6	24.2	5.4	15.9
HS04	48F	91	M	NA	NA	16.5	19.5	22.1	13.4	14.3	7.8	6.5
HS05	40BF	81	M	NA	NA	12.8	13.5	18.9	11.5	14.1	5.1	24.0
HS06	38BF	85	M	NA	NA	7.0	23.3	18.8	14.4	10.6	7.5	18.5
HS07	86BF	91	M	NA	NA	10.6	14.8	25.6	14.5	16.6	4.7	13.1
HS08	60G	93	F	NA	NA	7.9	9.7	18.3	12.3	21.7	11.5	18.6
HS09	132RS	94	F	NA	NA	17.6	15.5	9.3	8.8	21.6	5.1	22.1
HS10	108G	85	F	NA	NA	17.2	15.3	21.0	5.7	21.4	3.4	16.0
HS11	9RC	92	F	NA	NA	22.7	14.2	20.0	13.5	11.5	4.2	13.8
HS12	7RC	91	F	NA	NA	18.6	19.3	7.6	8.3	20.7	6.9	18.6
Mean						15.0	15.5	16.4	13.7	17.7	6.2	15.6
SD						4.7	3.9	6.0	5.8	4.9	2.1	5.2
PT03	6723	43	M	68 kg	Unknown	14.2	9.9	12.1	11.4	27.2	9.7	15.5
PT01	6464	26	F	81.6 kg	Head trauma	13.6	11.1	14.2	10.7	25.1	6.1	19.2
PT02	6463	25	F	42.4 kg	Unknown	12.4	7.3	16.7	15.0	21.4	9.1	17.9
PT04	6722	40	F	26 kg	Bronchopneumonia	11.3	9.5	10.5	15.7	21.6	18.2	13.1
PT05	7425	28	F	48 kg	Unknown	10.2	11.1	19.9	11.7	32.0	6.8	8.4
PT06	8066	47	F	46.6 kg	Atrial myxoma	12.3	11.0	13.6	12.5	25.6	5.2	19.8
Mean						12.3	10.0	14.5	12.9	25.5	9.2	15.7
SD						1.5	1.5	3.4	2.1	3.9	4.7	4.3
						$p = 0.19$	$p = 0.004^a$	$p = 0.49$	$p = 0.925$	$p = 0.004^a$	$p = 0.092$	$p = 0.99$

Abbreviations: a, adult; DRC, dorsal radiocarpal ligament; F, female; HS, *Homo sapiens*; LRL, long radiolunate ligament; M, male; NA, not available; PT, *pan troglodytes*; PUC, palmar ulnocarpal ligament; RC, radial collateral ligament; RSC, Radioscaphocapitate ligament; SD, standard deviation; SRL, short radiolunate ligament; UC, ulnar collateral ligament.

^aStatistical significance.

at the facilities of the Anatomical Museum of the University of Valladolid and included an adult male and five adult females. All the chimpanzee specimens came from different Spanish zoos and had died from causes unrelated to this study. The human samples came from the Body Donation Service of the University of Barcelona and included seven men and five women with an average age of 87.9 years (range 81–94 years). All individuals had been cryopreserved without chemical fixation within 24–48 h after death. Each specimen was completely defrosted approximately 24 h before dissection.

All dissections were performed by the same investigator (J.M.P.). All the muscles of the shoulder, arm, forearm and hand were isolated, and the ligaments of the radiocarpal joint were carefully dissected. All possible data on the anatomical characteristics of the muscles were collected before isolating them and weighing them with a precision scale (Kern-EW with a resolution of 0.001 g). Once the muscles were isolated, the insertion sites of each of the ligaments of the radiocarpal joint were examined. Passive flexion, extension, radial deviation and ulnar deviation of the wrist were then performed manually to confirm that the same groups of ligaments were tightened in both species when subjected to the same

maneuvers. Finally, the ligaments were isolated individually and weighed separately with a precision scale. In order to minimize the possible effects of moisture loss on the weight of the ligaments, all the specimens were dissected under similar temperature conditions (15–17°C) and in similar lengths of time (30–40 min), and once each ligament had been identified, it was covered with damp gauze while the other ligaments were being dissected. When all the ligaments were disinserted and removed, none of the radiocarpal joints studied were found to have anatomical alterations arising from the presence of fractures or joint degenerative processes.

Once the mass of the ligaments was quantified, the mass of each ligament was calculated relative to the total ligament mass. The ligaments were then classified into four groups: palmar (RSC + LRL + SRL + PUC ligaments); dorsal (DRC ligament); radial (RC ligament); and ulnar (UC ligament). The mass of each group was then calculated relative to the total ligament mass to enable comparison between differently-sized species.

Finally, the total mass of the forearm muscles that cross the radiocarpal joint, participating in its movement and stability, was obtained and these muscles were classified into the same functional groups as

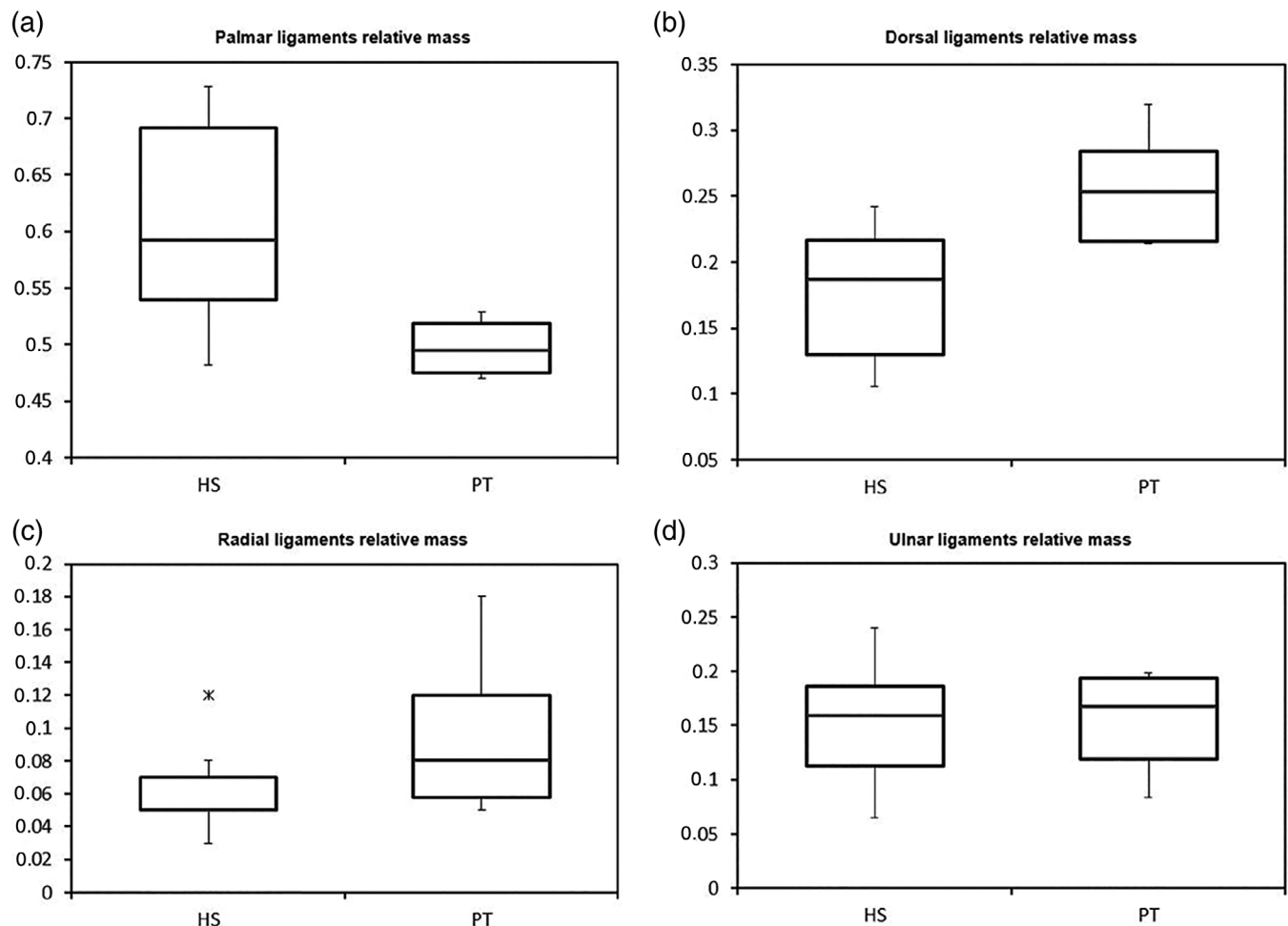


FIGURE 3 Boxplot of the relative mass of the (a) palmar ligaments, (b) dorsal ligaments, (c) radial ligaments, and (d) ulnar ligaments in humans and chimpanzees. HS = *Homo sapiens*; PT = *pan troglodytes*

the ligaments: palmar (*m. flexor digitorum superficialis* + *m. flexor pollicis longus* + *m. flexor digitorum profundus*); dorsal (*m. extensor digitorum* + *m. extensor digiti minimi* + *m. extensor pollicis longus* + *m. extensor indicis*); radial (*m. flexor carpi radialis* + *m. extensor carpi radialis longus* + *m. extensor carpi radialis brevis* + *m. abductor pollicis longus* + *m. extensor pollicis brevis*); and ulnar (*m. flexor carpi ulnaris* + *m. extensor carpi ulnaris*). The *m. flexor pollicis longus* and the *m. extensor pollicis brevis* are characteristic of humans and are not present in chimpanzees. The muscle mass of each group was then calculated relative to the total muscle mass.

2.2 | Statistical analyses

Sample normality was tested in PAST software using the Shapiro-Wilk and Anderson-Darling tests. The relative mass of each ligament, the relative mass of each ligament group, and the relative mass of each muscle group were compared between chimpanzees and humans using the parametric *T*-test and the nonparametric Mann-Whitney *U* test. Statistical significance was set at $p \leq 0.05$.

2.3 | Ethical note

The research complied with protocols approved by the Institutional Animal Care and Use Committee of the University of Barcelona.

3 | RESULTS

3.1 | Qualitative analysis

In all chimpanzees, the anatomical arrangement of the ligaments of the radiocarpal joint was similar to that of the human specimens. In the palmar region (Figure 1), the PRC ligament (comprising the RSC, LRL and SRL ligaments) and the PUC ligament were identified. In the dorsal region (Figure 2), the DRC ligament was identified as the only stabilizing ligament. In the radial and ulnar regions (Figures 1 and 2), the RC and UC ligaments, respectively, were identified. As previously described in humans (Apergis, 2013), the RSC ligament in the chimpanzee specimens extended from the palmar surface of the radial styloid process to the scaphoid and capitate, the LRL ligament extended

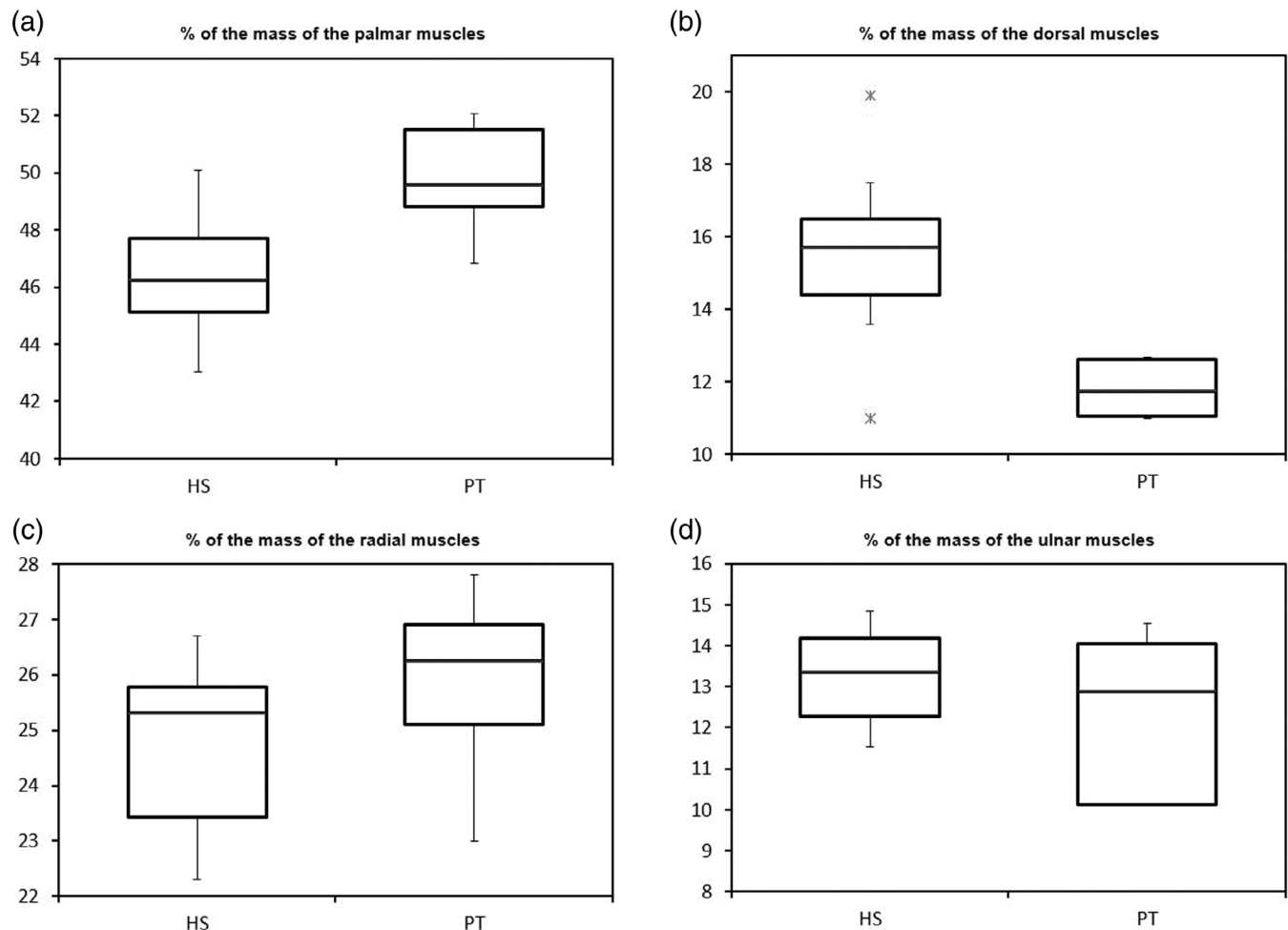


FIGURE 4 Boxplot of the relative mass of the (a) palmar muscles, (b) dorsal muscles, (c) radial muscles, and (d) ulnar muscles in humans and chimpanzees. HS = *Homo sapiens*; PT = *pan troglodytes*

from the palmar surface of the radial scaphoid fossa to the lunate, and the SRL ligament extended from the palmar surface of the radial lunate fossa to the lunate. In the radial region, the RC ligament extended between the radial styloid process and the scaphoid, while in the ulnar region, the UC ligament connected the ulnar styloid process, the pisiform and the triquetrum (Figures 1 and 2). In the dorsal region of the chimpanzee wrist, the DRC ligament was larger than in humans (Figure 2), as can be seen in the proximal insertion of the DRC ligament. While in humans, it is inserted in the central region of the dorsal edge of the distal radial epiphysis, distally and ulnarly to the dorsal tubercle (Figure 2), in chimpanzees, the insertion is more pronounced and extends along the entire dorsal edge of the distal radial epiphysis (Figure 2). Distally, the DRC ligament extends to the lunate and the triquetrum in both chimpanzees and humans.

The passive maneuvers performed after the removal of the muscles and the identification of the radiocarpal ligaments revealed that the four palmar ligaments (RSC, LRL, SRL and PUC) are tightened during wrist extension, the RSC and LRL ligaments are tightened during wrist ulnar deviation, and the SRL and PUC ligaments are tightened during wrist radial deviation. The DRC ligament tightens during wrist flexion, the RC ligament tightens during wrist ulnar deviation, and the UC ligament tightens during wrist radial deviation.

3.2 | Quantitative analysis

The absolute values of the mass of the ligaments are shown in Table S1. The relative mass of the palmar group of ligaments was significantly higher in humans than in chimpanzees (0.61 in humans vs. 0.50 in chimpanzees; $p = 0.005$), while the relative mass of the dorsal group of ligaments was significantly higher in chimpanzees than in humans (0.25 in chimpanzees vs. 0.18 in humans; $p = 0.001$) (Figure 3 and Table S2). However, no significant differences were observed between the relative mass of the radial group (0.06 in humans vs. 0.09 in chimpanzees; $p = 0.092$) or the ulnar group (0.16 in humans vs. 0.16 in chimpanzees; $p = 1.000$) (Figure 3). The mass of each of the individual ligaments of the palmar group relative to the total ligament mass was always higher in humans (Table 1), but these differences were only significant for the LRL ligament (15.5% in humans vs. 10.0% in chimpanzees; $p = 0.004$). Significant differences between humans and chimpanzees were also observed when comparing the relative mass of the three ligaments of the PRC ligament (RSC, LRL and SRL), which are the main stabilizers of the radiocarpal joint (46.9% in humans vs. 36.8% in chimpanzees; $p = 0.007$).

Finally, the analysis of the stabilizing muscles of the radiocarpal joint showed that the relative mass of the palmar group of muscles was significantly higher in chimpanzees than in humans (49.8% in chimpanzees vs. 46.5% in humans; $p = 0.004$), while the relative mass of the dorsal group of muscles was significantly higher in humans than in chimpanzees (15.5% in humans vs. 11.9% in chimpanzees; $p < 0.001$) (Figure 4 and Table S3). No significant differences between humans and chimpanzees were observed in the relative mass of the radial and ulnar groups of muscles (Figure 4 and Table S3). These

results were confirmed when we compared the ratio between the palmar and dorsal flexors in humans and chimpanzees (4.23 in chimpanzees vs. 3.06 in humans; $p = 0.002$) and between the radial and ulnar deviators, which were similar in the two species (2.15 in chimpanzees vs. 1.89 in humans; $p = 0.335$).

4 | DISCUSSION

There are functional differences between the radiocarpal joint in humans and in chimpanzees, mainly due to the greater compressive and tensile forces arising from the locomotor behavior of chimpanzees (Sarmiento, 1988). In modern humans, the radiocarpal joint is mainly involved in manipulative functions, while in chimpanzees, in addition to a manipulative use (Zihlman & Underwood, 2019), it participates directly in knuckle-walking, which generates compressive forces (Thompson et al., 2018; Tuttle, 1969), and in different forms of suspensory behavior, such as clambering or vertical climbing, which place tension on the wrist (Hunt, 1991). In the present study, however, we have observed that these functional differences between the two species in the radiocarpal joint do not translate into large qualitative anatomical differences in their ligaments. We have identified the same ligaments and a similar anatomical arrangement in our specimens of chimpanzees and humans (Apergis, 2013). The only marked qualitative difference between the two species was the greater extension of the proximal insertion of the DRC ligament in chimpanzees (Figure 2), which is linked to the larger dimensions of this ligament, as confirmed in the subsequent quantitative analysis.

The quantitative analysis indicated that, even though the body mass of adult humans can be double that of adult chimpanzees, the total mass of the wrist ligaments was larger in chimpanzees compared to humans (Table S1), which was to be expected in a joint subjected to the compressive and tensile forces arising from the locomotor behavior of chimpanzees (Hunt, 1991; Tuttle, 1969). Surprisingly, however, these differences were only significant for the DRC and RC ligaments, while the other ligaments had similar values in the two species and the absolute mass of the LRL ligament was even slightly larger in humans. This finding may indicate that the greater stability of the wrist of chimpanzees compared to that of humans (Hunt, 1991; Kelly, 2001; Orr, 2017; Richmond et al., 2001) is more due to the anatomy of bone surfaces than to the morphological characteristics of ligaments. Among the bone characteristics that limit wrist extension in chimpanzees are the development of the scaphoid beak on the dorsal aspect of this bone that is in contact with the dorsal aspect of the distal radial epiphysis (Orr, 2017) and the marked distal projection of the dorsal aspect of this distal epiphysis, that is characteristic of all hominoid primates except humans (Orr, 2017; Richmond et al., 2001; Richmond & Strait, 2000; Tallman, 2012; Tuttle, 1969).

When comparing the ligament groups between chimpanzees and humans (Table S2), we observed that the humans had a greater relative mass of the palmar ligaments, while the chimpanzees had a greater relative mass of the dorsal ligaments (Figure 3). This feature of the palmar ligaments in humans may be related to the fact that in

humans, wrist extension is necessary for effective manipulative function and maximum strength (Hazelton et al., 1975; Volz et al., 1980). Of the four palmar ligaments of the radiocarpal joint, the three that form the PRC ligament (RSC, LRL and SRL) are the main stabilizing elements of the radiocarpal joint in humans (Apergis, 2013). These three ligaments are tightened during wrist extension, stabilizing the scaphoid (RSC ligament) and the lunate (LRL and SRL ligaments) (Ringler & Murthy, 2015), and their combined relative mass was significantly higher in humans than in chimpanzees (46.9% vs. 36.8%; $p = 0.007$). Of these three palmar ligaments, only the LRL ligament had a significantly higher relative mass in humans compared to chimpanzees (Table 1). Because the main function of the LRL ligament is the stabilization of the lunate during wrist extension (Apergis, 2013; Ringler & Murthy, 2015), we can speculate that its higher relative mass in humans compared to chimpanzees compensates for the absence of bone characteristics that stabilize the lunate in chimpanzees. These stabilizing characteristics include both the distal projection of the dorsal aspect of the distal radial epiphysis and the dorsopalmar and mediolateral expansion of the lunate, which creates a large surface for the radius that can better absorb the large loads to which the radiolunate joint is subjected during arboreal locomotion and knuckle-walking (Kivell et al., 2013). In humans, the lack of development of these stabilizing adaptations implies a greater mobility of the wrist that allows a more effective manipulative function (Heinrich et al., 1993).

On the other hand, the larger relative mass of the dorsal ligament group in chimpanzees was related to the dimensions of the DRC ligament, which had a significantly higher relative mass in chimpanzees than in humans (25.5% in chimpanzees vs. 17.7% in humans; $p = 0.004$). In humans, the DRC ligament tightens during wrist flexion to stabilize the scaphoid, lunate and triquetrum (Rainbow et al., 2012). The fact that the insertion sites of the DRC ligament are the same in chimpanzees and in humans and that it is tightened during wrist flexion in both species may indicate that it is an important stabilizer of the proximal carpal bones during wrist flexion in chimpanzees, and its greater mass may be related to the need for stabilizing the wrist in flexion during locomotion. During the support phase of knuckle-walking, the chimpanzee wrist is slightly in extension (Kivell & Schmitt, 2009; Thompson, 2020), so the stabilizing function of the DRC ligament would be less important, since the stability of the radiocarpal joint in extension is guaranteed in chimpanzees by the stabilizing osteological mechanisms (Kivell & Schmitt, 2009; Orr, 2017; Richmond et al., 2001; Richmond & Strait, 2000; Tuttle, 1969). These mechanisms are highly effective, since cineradiographic studies (Jenkins & Fleagle, 1975) have shown that the proximal carpal remains static during the support phase of knuckle-walking (Richmond & Strait, 2000). Moreover, during this phase, chimpanzees do not recruit the flexor muscles of the wrist and fingers to ensure the stability of the wrist in extension, indicating that this stability is passively obtained (Leijnse et al., 2021; Richmond & Strait, 2000; Susman & Stern, 1979). Also, it has been observed that the ground reaction forces generated in the upper extremity of chimpanzees during the support phase of knuckle-walking do not generate high impact peaks (Pontzer et al., 2014; Thompson et al., 2018) and thus do not require the wrist ligaments to stabilize the radiocarpal joint during this phase.

In contrast with knuckle-walking, during vertical climbing and other suspensory behavior, the wrist of chimpanzees is in flexion, and the larger the diameter of the support structure, the greater degree of flexion (Sarmiento, 1988). Unlike wrist extension, during wrist flexion, chimpanzees have no osteological mechanisms to stabilize the radiocarpal joint. Therefore, the DRC ligament plays an important stabilizing role during vertical climbing and other suspensory behavior, which would explain the greater relative mass of this ligament in chimpanzees compared to humans, as observed in the present study. In addition, during vertical climbing and suspensory behavior, large loads are placed on the radiolunate joint of chimpanzees (Kivell et al., 2013), which would also explain the larger mass of the DRC ligament in these primates, since this ligament is the main stabilizing element of the lunate during wrist flexion (Rainbow et al., 2012).

In addition to wrist flexion, wrist ulnar deviation also occurs in chimpanzees during vertical climbing and other suspensory behavior (Hunt, 1991; Kivell et al., 2013; Sarmiento, 1988), as well as during the stance phase and weight-bearing touchdown of knuckle-walking (Sarmiento, 1988; Thompson, 2020; Whitehead, 1993). However, this ulnar deviation of the radiocarpal joint during locomotion does not translate into a greater relative mass of the RC ligament in chimpanzees (Table 1). In humans, the RC ligament is slightly controversial, as some investigators believe it should be considered the radial part of the RSC ligament rather than a separate ligament (Apergis, 2013; Ringler & Murthy, 2015). However, in our chimpanzees, we were able to identify a RC ligament that was perfectly differentiated from the RSC ligament (Figure 1).

Our analysis of the relative mass of the periarticular muscles of the wrist showed that in both chimpanzees and humans, the muscle and ligament patterns had an inverse relationship (Figures 3 and 4). In the chimpanzees, the lesser relative mass of the LRL ligament was counterbalanced by a greater relative mass of the palmar muscles, while in humans, the lesser relative mass of the DRC ligament was counterbalanced by the greater relative mass of the dorsal muscles (Table S3). This finding is pertinent to previous reports that the DRC ligament in humans has a greater innervation than the palmar ligaments, which may be related to the importance of ligament-muscular reflexes in the dorsal stabilization of the wrist (Hagert et al., 2007). Thus, it can be concluded that in humans, the DRC ligament has an important function as a generator of proprioceptive information (Apergis, 2013), while in chimpanzees, it is predictable that this ligament will present a more mechanical function. We found no differences between humans and chimpanzees in the relative mass of the radial and ulnar muscles (Figure 4 and Table S3), which is consistent with the lack of significant differences between the two species in the relative mass of the radial and ulnar ligaments (Figure 3 and Table S2). This observation does not support our hypothesis that the RC ligament would be more developed in chimpanzees.

In conclusion, our analyses of the ligaments of the radiocarpal joint in chimpanzees and humans have identified differences that may well be related to the different use of the wrist in the two species. These differences were more evident in the quantitative than the qualitative parameters. In humans, we observed a greater relative

mass of the palmar ligaments, in particular the LRL, which is related to the importance of wrist extension during manipulative tasks (Hazelton et al., 1975; Volz et al., 1980), while in chimpanzees, we found a greater relative mass of the dorsal ligament, namely DRC ligament, which is related to its role as a stabilizer of the radiocarpal joint in wrist flexion during vertical climbing and suspensory locomotion. Furthermore, our finding of an inverse relationship between muscle and ligament relative mass in both species, with a greater relative mass of the palmar muscles in chimpanzees and the dorsal muscles in humans, highlights the importance of the cooperative role of ligaments and muscles in stabilizing joints (Hagert et al., 2007; Hagert et al., 2009).

Our study provides novel information on wrist ligaments in chimpanzees—structures that generally receive little attention in comparative anatomy studies. Having been able to access six specimens of chimpanzees—a relatively large number in soft tissue studies of hominines—we were able to statistically compare quantitative data on wrist ligaments and muscles. Ideally, however, a further study with a larger number of hominoid primate specimens and species would allow us to validate our findings and evaluate if these also hold true in primates with different types of locomotion.

Our results will contribute to a better understanding of the anatomical and functional characteristics of the wrist region in hominines and will be useful in diverse disciplines, including comparative anatomy, physical anthropology and evolutionary anatomy. In addition, since some of the ligaments studied leave recognizable marks on the distal radial epiphysis (Casado et al., 2019), whose morphological characteristics can be related to different types of locomotion in primates, our findings can help to assign a specific type of locomotion to fossil hominoid primates based on the study of preserved distal radial epiphyses. For example, in a fossil primate with an intact distal radial epiphysis, we could deduce that a greater relative size of the insertion site of the RSC and LRL ligaments would indicate a greater relative mass of these ligaments (Casado et al., 2019) and a use of the upper extremity similar to modern humans.

The main limitations of this study are related to the characteristics of the specimens. The human specimens were obtained from the Body Donation Service of the Human Anatomy Unit of the University of Barcelona. Cadavers donated to the Service are divided into specific anatomical regions upon arrival, making it impossible for us to know the total body weight of each individual, which would have helped in the scaling of ligament mass. Moreover, cadavers donated to the Service are usually elderly individuals, in whom the ligaments can be deteriorated. We minimized the possible effect of this age-related deterioration as much as possible by excluding specimens showing signs of degeneration, trauma, or macroscopic indications of degradation. Finally, although we used the parameter of relative mass to compare the ligaments of the radiocarpal joint in humans and chimpanzees, our findings warrant further functional analyses based on other quantifiable parameters of the ligaments, such as cross-sectional area, stiffness, and failure strength.

ACKNOWLEDGMENTS

The authors thank Manuel Martín, Sebastián Mateo, and Pau Rigol (Body Donation Service, University of Barcelona) for their support

and collaboration, and Renee Grupp for assistance in drafting the manuscript. We also thank the zoos that provided the chimpanzees included in the study: the Zoo of Madrid, the Bioparc of Fuengirola, the Primadomus of Alicante, and the Zoo of Santillana. This work was supported by the Ministerio de Economía y Competitividad of Spain (grant number CGL2014-52611-C2-2-P to Josep Maria Potau), the European Union (FEDER) (grant number CGL2014-52611-C2-2-P to Josep Maria Potau) and by the Ajudes Predoctorals of the University of Barcelona (grant number APIF-UB 2016/2017 to Aroa Casado).

CONFLICT OF INTERESTS

The authors declare that they have no conflicts of interest.

AUTHOR CONTRIBUTIONS

Josep Maria Potau: Conceptualization (lead); data curation (lead); formal analysis (lead); funding acquisition (lead); investigation (lead); methodology (lead); project administration (lead); resources (lead); software (lead); supervision (lead); validation (lead); visualization (lead); writing – original draft (lead); writing – review and editing (lead). **Juan Francisco Pastor:** Conceptualization (supporting); data curation (lead); investigation (equal); methodology (equal); resources (equal); validation (equal); visualization (equal); writing – review and editing (equal). **Félix Jesús de Paz:** Conceptualization (supporting); data curation (supporting); investigation (equal); methodology (equal); resources (equal); validation (equal); visualization (equal); writing – review and editing (equal). **Mercedes Barbosa:** Conceptualization (supporting); data curation (supporting); investigation (equal); methodology (equal); resources (equal); validation (equal); visualization (equal); writing – review and editing (equal). **Mónica Gómez:** Conceptualization (supporting); investigation (equal); methodology (equal); resources (supporting); software (supporting); validation (equal); writing – review and editing (equal). **Marina de Diego:** Conceptualization (supporting); investigation (equal); methodology (equal); resources (supporting); software (supporting); validation (equal); writing – review and editing (equal). **Aroa Casado:** Conceptualization (supporting); data curation (equal); funding acquisition (lead); investigation (equal); methodology (equal); resources (equal); software (equal); validation (equal); visualization (equal); writing – review and editing (equal).

DATA AVAILABILITY STATEMENT

The data that support the findings of this study are available from the corresponding author upon reasonable request.

ORCID

Josep Maria Potau  <https://orcid.org/0000-0003-3387-8760>

REFERENCES

- Almécija, S., Hammond, A. S., Thompson, N. E., Pugh, K. D., Moyà-Solà, S., & Alba, D. M. (2021). Fossil apes and human evolution. *Science*, 372, eabb4363.
- Apergis, E. (2013). *Fracture-dislocations of the wrist*. Springer.
- Berger, R. A. (1997). The ligaments of the wrist: A current overview of anatomy with considerations of their potential functions. *Hand Clinics*, 13, 63–82.

- Breen, E. C. (2000). Mechanical strain increases type I collagen expression in pulmonary fibroblasts in vitro. *Journal of Applied Physiology*, 88, 203–209.
- Brown, R. R., Fliszar, E., Cotten, A., Trudell, D., & Resnick, D. (1998). Extrinsic and intrinsic ligaments of the wrist: Normal and pathologic anatomy at MR arthrography with three-compartment enhancement. *Radiographics*, 18, 667–674.
- Buijze, G. A., Lozano-Calderon, S. A., Strackee, S. D., Blankevoort, L., & Jupiter, J. B. (2011). Osseous and ligamentous scaphoid anatomy: Part I. A systematic literature review highlighting controversies. *Journal of Hand Surgery*, 36, 1926–1935.
- Cardoso, R., & Szabo, R. M. (2007). Wrist anatomy and surgical approaches. *Orthopedic Clinics of North America*, 38, 127–148.
- Carlson, K. J. (2006). Muscle architecture of the common chimpanzee (*pan troglodytes*): Perspectives for investigating chimpanzee behavior. *Primates*, 47, 218–229.
- Casado, A., Punsola, V., Gómez, M., de Diego, M., Barbosa, M., de Paz, F. J., Pastor, J. F., & Potau, J. M. (2019). Three-dimensional geometric morphometric analysis of the distal radius insertion sites of the palmar radiocarpal ligaments in hominoid primates. *American Journal of Physical Anthropology*, 170, 24–36.
- Drapeau, M. S. M., & Ward, C. V. (2007). Forelimb segment length proportions in extant hominoids and *Australopithecus afarensis*. *American Journal of Physical Anthropology*, 132, 327–343.
- Gebo, D. L. (2014). *Primate comparative anatomy*. Johns Hopkins University Press.
- Goodall, J. (1986). *Chimpanzees of Gombe*. Harvard University Press.
- Hagert, E., Garcia-Elias, M., Forsgren, S., & Ljung, B. O. (2007). Immunohistochemical analysis of wrist ligament innervation in relation to their structural composition. *Journal of Hand Surgery. American Volume*, 32, 30–36.
- Hagert, E., Persson, J. K. E., Werner, M., & Ljung, B. O. (2009). Evidence of wrist proprioceptive reflexes elicited after stimulation of the scapholunate interosseous ligament. *Journal of Hand Surgery. American Volume*, 34, 642–651.
- Hazelton, F. T., Smidt, G. L., Flatt, A. E., & Stephens, R. I. (1975). The influence of wrist position on the force produced by the finger flexors. *Journal of Biomechanics*, 8, 301–306.
- Heinrich, R. E., Rose, M. D., Leakey, R. E., & Walker, A. C. (1993). Hominid radius from the middle Pliocene of Lake Turkana, Kenya. *American Journal of Physical Anthropology*, 92, 139–148.
- Hernandez-Aguilar, R. A., Moore, J., & Pickering, T. R. (2007). Savanna chimpanzees use tools to harvest the underground storage organs of plants. *Proceedings of the National Academy of Sciences*, 104, 19210–19213.
- Hopkins, W. D., Cantalupo, C., Wesley, M. J., Hostetter, A. B., & Pilcher, D. L. (2002). Grip morphology and hand use in chimpanzees (*pan troglodytes*). *Journal of Experimental Psychology. General*, 131, 412–423.
- Hunt, K. D. (1991). Mechanical implications of chimpanzee positional behavior. *American Journal of Physical Anthropology*, 86, 521–536.
- Jenkins, F. A. J., & Fleagle, J. G. (1975). In R. Tuttle (Ed.), *Knuckle-walking and the functional anatomy of the wrists in living apes*. The Hague.
- Kelly, R. E. (2001). Tripedal knuckle-walking: A proposal for the evolution of human locomotion and handedness. *Journal of Theoretical Biology*, 213, 333–358.
- Kivell, T. L., Barros, A. P., & Smaers, J. B. (2013). Different evolutionary pathways underlie the morphology of wrist bones in hominoids. *BMC Evolutionary Biology*, 13, 229.
- Kivell, T. L., & Schmitt, D. (2009). Independent evolution of knuckle-walking in African apes shows that humans did not evolve from a knuckle-walking ancestor. *Proceedings of the National Academy of Sciences*, 106, 14241–14246.
- Leijnse, J. N., Spoor, C. W., Pullens, P., & Vereecke, E. E. (2021). Kinematic and dynamic aspects of chimpanzee knuckle walking: Finger flexors likely do not buffer ground impact forces. *Journal of Experimental Biology*, 224, jeb236604.
- Marzke, M. W., Marchant, L. F., McGrew, W. C., & Reece, S. P. (2015). Grips and hand movements of chimpanzees during feeding in Mahale Mountain National Park, Tanzania. *American Journal of Physical Anthropology*, 156, 317–326.
- Marzke, M. W., Marzke, R. F., Linscheid, R. L., Smutz, P., Steinberg, B., Reece, S., & An, K. N. (1999). Chimpanzee thumb muscle cross sections, moment arms and potential torques, and comparisons with humans. *American Journal of Physical Anthropology*, 110, 163–178.
- Michilsens, F., Vereecke, E. E., D'Août, K., & Aerts, P. (2009). Functional anatomy of the gibbon forelimb: Adaptations to brachiating lifestyle. *Journal of Anatomy*, 215, 335–354.
- Myatt, J. P., Crompton, R. H., Payne-Davis, R. C., Vereecke, E. E., Isler, K., Savage, R., D'Août, K., Günther, M. M., & Thorpe, S. K. S. (2012). Functional adaptations in the forelimb muscles of non-human great apes. *Journal of Anatomy*, 220, 13–28.
- Nordin, M., & Frankel, V. H. (2001). *Basic biomechanics of the musculoskeletal system*. Lippincott Williams and Wilkins.
- Oishi, M., Ogihara, N., Endo, H., Ichihara, N., & Asari, M. (2009). Dimensions of forelimb muscles in orangutans and chimpanzees. *Journal of Anatomy*, 215, 373–382.
- Orlandi, D., Fabbro, E., Ferrero, G., Martini, C., Lacelli, F., Serafini, G., Silvestri, E., & Sconfienza, L. M. (2012). High resolution ultrasound of the extrinsic carpal ligaments. *Journal of Ultrasound*, 15, 267–272.
- Orr, C. M. (2017). Locomotor hand postures, carpal kinematics during wrist extension, and associated morphology in anthropoid primates. *Anatomical Record*, 300, 382–401.
- Palmer, A. K., & Werner, F. W. (1981). The triangular fibrocartilage complex of the wrist: Anatomy and function. *Journal of Hand Surgery. American Volume*, 6, 153–162.
- Pontzer, H., Raichlen, D. A., & Rodman, P. S. (2014). Bipedal and quadrupedal locomotion in chimpanzees. *Journal of Human Evolution*, 66, 64–82.
- Potau, J. M., Bardina, X., Ciurana, N., Camprubi, D., Pastor, J. F., de Paz, F., & Barbosa, M. (2009). Quantitative analysis of the deltoid and rotator cuff muscles in humans and great apes. *International Journal of Primatology*, 30, 697–708.
- Prüfer, K., Munch, K., Hellmann, I., Akagi, K., Miller, J. R., Walenz, B., Koren, S., Sutton, G., Kodira, C., Winer, R., Knight, J. R., Mullikin, J. C., Meader, S. J., Ponting, C. P., Lunter, G., Higashino, S., Hobolth, A., Duthheil, J., Karakoç, E., ... Pääbo, S. (2012). The bonobo genome compared with the chimpanzee and human genomes. *Nature*, 486, 527–531.
- Rainbow, M. J., Crisco, J. J., Moore, D. C., Kamal, R. N., Laidlaw, D. H., Akelman, E., & Wolfe, S. W. (2012). Elongation of the dorsal carpal ligaments: A computational study of in vivo carpal kinematics. *Journal of Hand Surgery. American Volume*, 37, 1393–1399.
- Richmond, B. G., Begun, D. R., & Strait, D. S. (2001). Origin of human bipedalism: The knuckle-walking hypothesis revisited. *Yearbook of Physical Anthropology*, 44, 70–105.
- Richmond, B. G., & Strait, D. S. (2000). Evidence that humans evolved from a knuckle-walking ancestor. *Nature*, 404, 382–385.
- Ringler, M. D. (2013). MRI of wrist ligaments. *Journal of Hand Surgery*, 38, 2034–2046.
- Ringler, M. D., & Murthy, N. S. (2015). MR imaging of wrist ligaments. *Magnetic Resonance Imaging Clinics of North America*, 23, 367–391.
- Sarmiento, E. E. (1988). Anatomy of the hominoid wrist joint: Its evolutionary and functional implications. *International Journal of Primatology*, 9, 281–345.
- Shrewsbury, M. (2003). Pollical oblique ligament in humans and non-human primates. *Journal of Anatomy*, 202, 397–407.
- Susman, R. L., & Stern, J. T. (1979). Telemetered electromyography of flexor digitorum profundus and flexor digitorum superficialis in *pan troglodytes* and implications for interpretation of the O.H. 7 hand. *American Journal of Physical Anthropology*, 50, 565–574.
- Taleisnik, J. (1985). *The wrist*. Churchill Livingstone.
- Taljanovic, M. S., Goldberg, M. R., Sheppard, J. E., & Rogers, L. F. (2011). US of the intrinsic and extrinsic wrist ligaments and triangular

- fibrocartilage complex: Normal anatomy and imaging technique. *RadioGraphics*, 31, e44. <https://doi.org/10.1148/rg.e44>
- Tallman, M. (2012). Morphology of the distal radius in extant hominoids and fossil hominins: Implications for the evolution of bipedalism. *Anatomical Record*, 295, 454–464.
- Thompson, N. E. (2020). The biomechanics of knuckle-walking: 3-D kinematics of the chimpanzee and macaque wrist, hand and fingers. *Journal of Experimental Biology*, 223, jeb224360. <https://doi.org/10.1242/jeb.224360>
- Thompson, N. E., Rubinstein, D., & Larson, S. G. (2018). Great ape thorax and shoulder configuration- An adaptation for arboreality or knuckle-walking? *Journal of Human Evolution*, 125, 15–26.
- Thorpe, S. K., Crompton, R. H., Günther, M. M., Ker, R. F., & McNeill, A. R. (1999). Dimensions and moment arms of the hind- and forelimb muscles of common chimpanzees (*pan troglodytes*). *American Journal of Physical Anthropology*, 110, 179–199.
- Tipton, C. M., James, S. L., Mergner, W., & Tcheng, T. K. (1970). Influence of exercise on strength of medial collateral ligaments of dogs. *American Journal of Physiology*, 218, 894–902.
- Tuttle, R., Basmajian, R. V., Regenos, E., & Shine, G. (1972). Electromyography of knuckle-walking: Results of four experiments on the forearm of *pan gorilla*. *American Journal of Physical Anthropology*, 37, 255–265.
- Tuttle, R. H. (1969). Knuckle-walking and the problem of human origins. *Science*, 166, 953–961.
- Van Leeuwen, T., Vanhoof, M. J. M., Kerkhof, F. D., Stevens, J. M. G., & Vereecke, E. E. (2018). Insights into the musculature of the bonobo hand. *Journal of Anatomy*, 233, 328–340.
- Van Leeuwen, T., Vanneste, M., Kerkhof, F. D., D'agostino, P., Vanhoof, M. J. M., Stevens, J. M., van Lenthe, G. H., & Vereecke, E. E. (2019). Mobility and structural constraints of the bonobo trapeziometacarpal joint. *Biological Journal of the Linnean Society*, 127, 681–693.
- Volz, R. G., Lieb, M., & Benjamin, J. (1980). Biomechanics of the wrist. *Clinical Orthopaedics*, 149, 112–117.
- Whitehead, P. F. (1993). In D. L. Gebo (Ed.), *Aspects of the anthropoid wrist and hand*. Northern Illinois University Press.
- Zihlman, A. L., & Underwood, C. E. (2019). *Ape anatomy and evolution*. CreateSpace, Amazon.

SUPPORTING INFORMATION

Additional supporting information may be found in the online version of the article at the publisher's website.

How to cite this article: Potau, J. M., Pastor, J. F., de Paz, F. J., Barbosa, M., Gómez, M., de Diego, M., & Casado, A. (2022). Comparative anatomy of the ligaments and muscles of the radiocarpal joint in chimpanzees and humans. *American Journal of Biological Anthropology*, 178(2), 301–311. <https://doi.org/10.1002/ajpa.24490>