

A New Manual Retinal Thickness Measurement Protocol to Evaluate High Myopia Patients

José Alberto de-Lázaro-Yagüe^a Alberto López-Miguel^a María Rosa Sanabria^{a, c}
Itziar Fernández-Martínez^{a, b} Rosa María Coco-Martín^a

^aIOBA, Universidad de Valladolid, Valladolid, and ^bThe Biomedical Research Networking Center in Bioengineering, Biomaterials and Nanomedicine (CIBER-BBN), and ^cComplejo Asistencial de Palencia, Palencia, Spain

Key Words

Pathologic myopia · Optical coherence tomography · Retinal thickness · Axial eye length · Repeatability

Abstract

Purpose: To validate a manual measurement protocol for quantifying retinal thickness (RT) using an optical coherence tomography (OCT) device in pathologic myopia patients.

Methods: The macular Cross Hair protocol of Stratus OCT3 (Carl Zeiss Meditec, Inc., Dublin, Calif., USA) was applied and manual RT gauging was performed using the caliper tool. Foveal and paramacular RT, located at 1 and 2 mm distances from the fovea in both vertical and horizontal scans, were measured. Three consecutive RT measurements were taken to assess measurement reliability. The within-subject coefficient of variation (CV_w) and intraclass correlation coefficients (ICC) were calculated to validate the manual method.

Results: The mean axial length of the 29 eyes assessed was 28.28 ± 2.72 mm and the mean spherical refraction was -13.61 ± 6.68 diopters. CV_w ranged from 0.86 to 8.73% and ICC varied from 0.81 to 0.98. **Conclusion:** A manual RT measurement protocol could reliably be used in the daily clinic for assessing pathologic myopic patients when OCT software segmentation fails.

© 2013 S. Karger AG, Basel

Introduction

Myopia is a refractive error in which the parallel rays entering the eye are focused ahead of the retina. Myopia is considered pathologic when the refractive error is above 6 diopters (D) [1]. The prevalence of high myopia has been estimated to be 2% of the population [2]. Additionally, the prevalence of pathologic myopia varies from 2% in Caucasians in occidental countries [3] to 9% in Asian populations [4].

Pathologic myopia is usually characterized by a congenital scleral weakness causing progressive globe enlargement, which produces an anomalous increase in the axial eye length [5]. The staphyloma is considered to be its hallmark lesion, and this leads to a number of variable degenerative ocular fundus and vitreoretinal changes including decreased retinal thickness (RT) [6, 7].

Optical coherence tomography (OCT) is a noninvasive procedure that can record transversal sections of the retina in vivo, using a coherent light based on Michelson interferometry. It provides high-quality cross-sectional col-

The present study has been partially presented at the 12th Euretina Congress (POS-2094) in Milan, Italy.

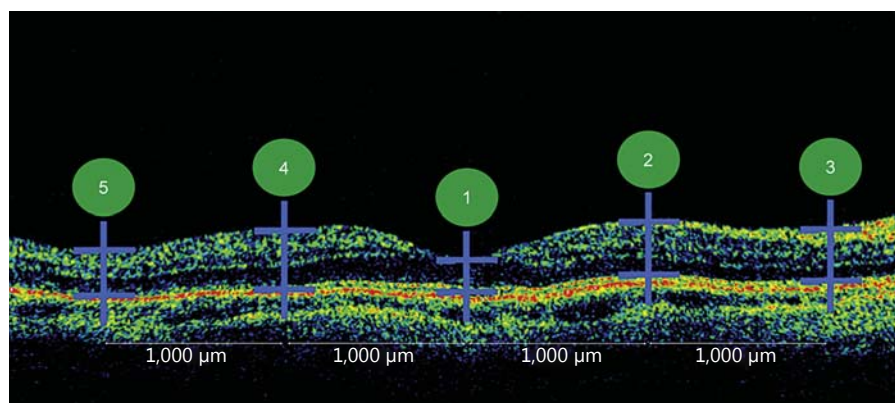


Fig. 1. Manual measurement protocol. Numbers indicate the measuring sequence.

or-coded reflectance map images of retinal tissue [8]. Although spectral-domain OCT is replacing time-domain OCT (TD-OCT), the latter is still widely used in ophthalmologic clinics all over the world. But the TD-OCT image quality obtained in pathologic myopia is frequently poorer than in healthy eyes, and it is common to find a curved-shape retinal image due to a posterior staphyloma; thus, it is expected that automated analysis protocols sometimes do not work correctly and predictably because accurate segmentation is not always obtained [9].

Precise RT measurements are important in daily clinic practice to avoid misleading diagnoses and to provide proper monitoring of the disease during follow-up. Consequently, manual gauging might be a good alternative when the segmentation software built into the TD-OCT device cannot properly identify retinal boundaries [10, 11], although it is a time-consuming procedure. However, manual RT estimation must also be reliable; thus, we designed a manual measurement protocol gauging not only the fovea but also paramacular localizations in eyes of long axial length, which could allow a more precise characterization of the retina in TD-OCT images of poor quality. Additionally, we calculated the intraobserver repeatability of this new RT measurement protocol in order to validate our manual procedure. Besides, findings on the reliability of RT measurement in pathologic myopia using a Stratus OCT3 device (Carl Zeiss Meditec, Inc., Dublin, Calif., USA) have not been published yet, although it was previously assessed in other retinal anomalies using the same TD-OCT [12, 13].

Materials and Methods

All procedures were performed in accordance with the Declaration of Helsinki. The study was performed after obtaining informed consent from the participants, and the local institutional

review board approved this study. All the patients included within our full diagnostic database between June 2010 and June 2011 at the IOBA Eye Institute (University of Valladolid, Spain) were considered for inclusion in this consecutive retrospective observational case series study. We only enrolled Caucasian myopic patients with a myopic refractive error above 6 D with available OCT images. The OCT examination was performed with the Cross Hair protocol, a vertical and a horizontal 6-mm retinal scan.

Patients with any other macular pathology that could have induced a change in RT (e.g. neovascular membranes, epiretinal membranes, macular retinoschisis, macular hole) or those with an OCT signal strength under 4 were excluded from the study.

Manual RT measurements were obtained in 29 patients by the ‘OCT RT’ analysis method, and the distance between OCT retinal boundaries was measured using the caliper tool. The manual procedure was performed by a single experienced examiner, who first placed the caliper at the level of the inner limiting membrane, and then at the level of the retinal pigment epithelium internal limit. The fovea was located first and then measured at its central thinnest point. Afterwards, RT was measured again at 1 and 2 mm from the fovea on vertical and horizontal scans. Therefore, the examiner obtained 10 RT measurements (5 from each retinal scan): a central one at the fovea and 2 nasally and 2 temporally in the horizontal scan; for the vertical scan, another 5 measurements were obtained: one in the center, 2 superiorly and 2 inferiorly (fig. 1).

To validate this new manual RT measurement protocol, its reliability was calculated analyzing the intrasession repeatability of the manual measurement. Thus, 10 eyes of 10 patients out of the 29 included in the study were selected following a computer-generated random table. The same experienced examiner obtained 3 RT measurements following the manual protocol in each of the 20 scans of the 10 eyes selected. To avoid subjective bias when using the caliper tool, the observer did not consecutively obtain the 3 RT measurements in each of the 5 RT locations of each scan. Actually, he gauged all the RT locations in the 20 scans of the 10 eyes selected once, and the following day, he performed the same measurement procedure again, and again on the third day, so that the examiner could not remember the previous RT values obtained for each RT location in all the scans. These data were used to estimate the manual RT measurement error.

Table 1. Repeatability outcomes of the manual measurement method

Retinal thickness localization	Overall mean RT ¹ , μm	SD _w , μm	Precision ² , μm	Coefficient of variation, %	ICC ³
Fovea (horizontal scan)	168.45 (116–215)	1.46	2.86	0.86	0.97 (0.90–0.99)
1 mm eccentricity nasally	271.76 (224–315)	9.33	18.28	3.43	0.88 (0.65–0.97)
2 mm eccentricity nasally	232.44 (157–273)	7.42	14.54	3.19	0.96 (0.88–0.98)
1 mm eccentricity temporally	266.76 (224–324)	12.66	24.81	4.74	0.89 (0.69–0.97)
2 mm eccentricity temporally	230.19 (190–290)	15.92	31.20	6.91	0.94 (0.83–0.98)
Fovea (vertical scan)	169.24 (124–207)	2.92	5.72	1.72	0.98 (0.94–0.99)
1 mm eccentricity superiorly	275.86 (190–331)	13.10	25.67	4.74	0.86 (0.61–0.96)
2 mm eccentricity superiorly	240.17 (190–273)	4.04	7.91	1.68	0.98 (0.94–0.99)
1 mm eccentricity inferiorly	274.31 (224–351)	23.95	46.94	8.73	0.81 (0.46–0.94)
2 mm eccentricity inferiorly	211.66 (165–257)	4.02	7.87	1.89	0.93 (0.81–0.98)

¹ Values in parentheses denote ranges. ² $1.96 \times SD_w$. ³ Values in parentheses denote 95% CI.

Statistical Analysis

The data were entered into a database, and statistical calculations performed by using SPSS version 18.0 for Windows (SPSS, Cary, N.C., USA). Intraobserver repeatability was assessed using the following parameters: within-subject standard deviation (SD_w) [14]; precision difference between a subject's measurement and the actual value for 95% of the observations (defined as $1.96 \times SD_w$); within-subject coefficient of variation (CV_w; the ratio of the SD_w of the repeated measurements to the mean) [14]; and intra-class correlation coefficient (ICC), a measurement of correlation or consistency for data sets of repeated measurements [15].

Results

The results were drawn from our 276 pathologic myopia cases from the database. Twenty-nine eyes of 19 patients (2 males and 17 females) complied with the inclusion criteria. The patients' mean age was 44.3 ± 13.5 years (range: 22–81 years). The mean spherical refraction was -13.61 ± 6.68 D (range: -6.00 to -25.00 D). The mean axial eye length was 28.28 ± 2.72 mm (range: 24.32–34.41 mm). The segmentation software correctly identified the retinal contour lines in 53 out of 58 scans analyzed (91.4%). The mean retinal OCT measurement quality (signal strength value) was 5.11 ± 1.44 (range: 4–7).

Reliability of Manual OCT Measurement

Overall average RT, intrasession SD_w, precision, CV_w and ICC values for intrasession repeatability are shown in table 1. Regarding SD_w, it was clinically acceptable for all the retinal locations selected, while ICC were clinically

excellent for all the locations except for the one located at 1 mm eccentricity inferiorly from the fovea, which can be qualified as good.

Discussion

OCT automatic analysis usually provides clinicians with high-value ocular information, leading to accurate diagnosis and therapeutics. However, in those cases where OCT images are of too poor a quality for proper built-in software segmentation proceeding, a manual RT measurement is recommended in the literature [10, 11]. The present study describes and validates for the first time a simple and consistent manual protocol which can help clinicians to perform an adequate foveal and paramacular assessment when OCT images in pathologic myopia are not of a high enough quality and the segmentation software fails. Therefore, clinical decision-making based on one single manual foveal thickness measurement can be avoided. Besides, the protocol might be used for research purposes in order to obtain comparable measures from the same patient at different times, or from different groups of patients, etc.

We decided to design a manual measurement protocol for assessing RT in pathologic myopia patients because Sadda et al. [16] found that 92% of the retinal OCT scans performed in macular diseases have some degree of segmentation error. Consequently, several authors [16, 17] have suggested the use of the OCT caliper tool

and to perform the measures manually in order to ensure proper RT measurement. Likewise, Eriksson et al. [18] have reported that repeatability of OCT RT measurements can be also increased in a Fourier-domain OCT system when the automatic segmentation software is manually relocated.

Repeatability of the manual RT measurements performed in our study was outstanding except for the RT located at 1 mm eccentricity inferiorly, which was only good (table 1). Previous authors have reported Stratus OCT repeatability when using automatic segmentation software in healthy patients having spherical refraction below 6 D [19]. As can be expected, their repeatability values (CV_w range: 0.65–2.29%) were much better than ours, which was directly related to their higher OCT image quality (mean signal strength = 7.34), allowing software segmentation to work more accurately. In addition, other authors [20] have also studied the repeatability of RT measurements in healthy children, following the same automatic methodology, and their outcomes were worse than in adults (CV_w range: 0.9–4.0%). However, on average their repeatability values were again better than ours. Nevertheless, it has to be taken into account that the automatic software usually follows the Early Treatment Diabetic Retinopathy Study (ETDRS) analysis protocol [19], which provides average RT values for determined areas instead of single-point RT values as we did; thus, variability must be expected to be lower when following the ETDRS protocol.

On the other hand, other authors have reported higher repeatability values when patients with age-related macular degeneration were examined. Krebs et al. [21] have found an SD_w value ranging from 27.91 to 42.41 μm for center point thickness, while our worst average SD_w value was 23.95 μm for the location at 1 mm inferior eccentricity (table 1). Nonetheless, when RT repeatability was studied in diabetic macular edema – a retinal anomaly that might not produce so much image distortion as exudative age-related macular degeneration does – SD_w repeatability values were reported to range from 7.8 to 17.9 μm [22]. However, these authors also used the ETDRS protocol; therefore, variability might be always lower than in single-point measurement. To sum up, our repeatability results for this new measurement protocol for manually obtaining RT values in eyes with pathologic myopia were good from a clinical point of view; therefore, it can be a useful measurement method for patients with pathologic myopia.

The main limitation of the present study is its design, as its retrospective nature did not allow us to repeat low-

quality image OCT, which would have provided a more reliable outcome due to greater OCT signal strength. Nevertheless, it was possible to perform proper manual measurements, and their repeatability was clinically acceptable, allowing the validation of the method. Secondly, the retinal scans were performed by a highly experienced practitioner who also manually adjusted RT measurements; thus, repeatability of the measurement protocol described could be worse in case RT measurements are obtained by nonexperienced examiners, which might reduce the validity of this manual method. Thirdly, manual RT measurement was performed using the Stratus OCT caliper tool; we assumed that this gauging tool is properly calibrated and we did not export the OCT scan to be processed using a special image software as other authors have previously reported [23]. Fourthly, the manual measurement protocol was validated in pathologic myopia patients without any other retinal anomaly; therefore, the validity of the method has to be proven again in highly myopic patients having their retinal structure altered (i.e. by choroidal neovascularization or myopic schisis). Fifthly, the present study was carried out using a TD-OCT device, despite the fact that spectral-domain OCT might provide a better image quality; however, nowadays there are numerous eye clinics worldwide that are still not able to afford the latest cutting-edge technology, and that still use high-value devices like TD-OCT. Finally, we did not carry out a direct comparison between manual and automatic RT measurements, because we performed RT gauging 1 and 2 mm away from the center, while the automatic software analysis provides RT measurements following the ETDRS grid, which offers average data for the central 1, 3 and 6 mm diameters (0.5, 1.5 and 3 mm away from the center).

In conclusion, we have validated a new manual RT measurement protocol that could be used in daily clinic practice when assessing highly myopic patients, with the aim of providing consistent OCT information when the image quality does not allow the segmentation software to work properly. This manual protocol is very valuable, especially for follow-up visits, and can help clinicians provide better counseling after making more adequate diagnostic and therapeutic decisions.

Disclosure Statement

None of the authors has any conflict of interest to disclose.

References

- 1 Saka N, Ohno-Matsui K, Shimada N, Sueyoshi S, Nagaoka N, Hayashi W, Hayashi K, Moriyama M, Kojima A, Yasuzumi K, Yoshida T, Tokoro T, Mochizuki M: Long-term changes in axial length in adult eyes with pathologic myopia. *Am J Ophthalmol* 2010; 150:562–568.e1.
- 2 Curtin BJ: *The Myopias: Basic Science and Clinical Management*. Philadelphia, Harper & Row, 1985.
- 3 Sperduto RD, Seigel D, Roberts J, Rowland M: Prevalence of myopia in the United States. *Arch Ophthalmol* 1983;101:405–407.
- 4 Wong TY, Foster PJ, Hee J, Ng TP, Tielsch JM, Chew SJ, Johnson GJ, Seah SK: Prevalence and risk factors for refractive errors in adult Chinese in Singapore. *Invest Ophthalmol Vis Sci* 2000;41:2486–2494.
- 5 Forte R, Cennamo G, Pascotto F, de Crecchio G: En face optical coherence tomography of the posterior pole in high myopia. *Am J Ophthalmol* 2008;145:281–288.
- 6 Curtin BJ, Karlin DB: Axial length measurements and fundus changes of the myopic eye. *Am J Ophthalmol* 1971;71:42–53.
- 7 Hsiang HW, Ohno-Matsui K, Shimada N, Hayashi K, Moriyama M, Yoshida T, Tokoro T, Mochizuki M: Clinical characteristics of posterior staphyloma in eyes with pathologic myopia. *Am J Ophthalmol* 2008;146:102–110.
- 8 van Velthoven ME, Faber DJ, Verbraak FD, van Leeuwen TG, de Smet MD: Recent developments in optical coherence tomography for imaging the retina. *Prog Retin Eye Res* 2007; 26:57–77.
- 9 Hee MR: Artifacts in optical coherence tomography topographic maps. *Am J Ophthalmol* 2005;139:154–155.
- 10 Krebs I, Binder S, Stolba U, Glittenberg C, Brannath W, Goll A: Choroidal neovascularization in pathologic myopia: three-year results after photodynamic therapy. *Am J Ophthalmol* 2005;140:416–425.
- 11 Garcia-Layana A, Salinas-Alaman A, Maldonado MJ, Sainz-Gomez C, Fernandez-Hortelano A: Optical coherence tomography to monitor photodynamic therapy in pathological myopia. *Br J Ophthalmol* 2006;90:555–558.
- 12 Patel PJ, Chen FK, Ikeji F, Tufail A: Intersession repeatability of optical coherence tomography measures of retinal thickness in early age-related macular degeneration. *Acta Ophthalmol* 2011;89:229–234.
- 13 Danis RP, Fisher MR, Lambert E, Goulding A, Wu D, Lee LY: Results and repeatability of retinal thickness measurements from certification submissions. *Arch Ophthalmol* 2008; 126:45–50.
- 14 Bland JM, Altman DG: Measurement error. *BMJ* 1996;313:744.
- 15 Bland JM, Altman DG: Measurement error and correlation coefficients. *BMJ* 1996;313: 41–42.
- 16 Sadda SR, Wu Z, Walsh AC, Richine L, Dougall J, Cortez R, LaBree LD: Errors in retinal thickness measurements obtained by optical coherence tomography. *Ophthalmology* 2006;113:285–293.
- 17 Taban M, Sharma S, Williams DR, Waheed N, Kaiser PK: Comparing retinal thickness measurements using automated fast macular thickness map versus six-radial line scans with manual measurements. *Ophthalmology* 2009;116:964–970.
- 18 Eriksson U, Alm A, Larsson E: Is quantitative spectral-domain superior to time-domain optical coherence tomography (OCT) in eyes with age-related macular degeneration? *Acta Ophthalmol* 2012;90:620–627.
- 19 Eriksson U, Alm A: Repeatability in and interchangeability between the macular and the fast macular thickness map protocols: a study on normal eyes with Stratus optical coherence tomography. *Acta Ophthalmol* 2009;87:725–730.
- 20 Eriksson U, Holmström G, Alm A, Larsson E: A population-based study of macular thickness in full-term children assessed with Stratus OCT: normative data and repeatability. *Acta Ophthalmol* 2009;87:741–745.
- 21 Krebs I, Hagen S, Brannath W, Haas P, Womastek I, de Salvo G, Ansari-Shahrezaei S, Binder S: Repeatability and reproducibility of retinal thickness measurements by optical coherence tomography in age-related macular degeneration. *Ophthalmology* 2010;117: 1577–1584.
- 22 Forooghian F, Cukras C, Meyerle CB, Chew EY, Wong WT: Evaluation of time domain and spectral domain optical coherence tomography in the measurement of diabetic macular edema. *Invest Ophthalmol Vis Sci* 2008;49:4290–4296.
- 23 Leung CK, Chan WM, Chong KK, Chan KC, Yung WH, Tsang MK, Tse RK, Lam DS: Alignment artifacts in optical coherence tomography analyzed images. *Ophthalmology* 2007;114:263–270.